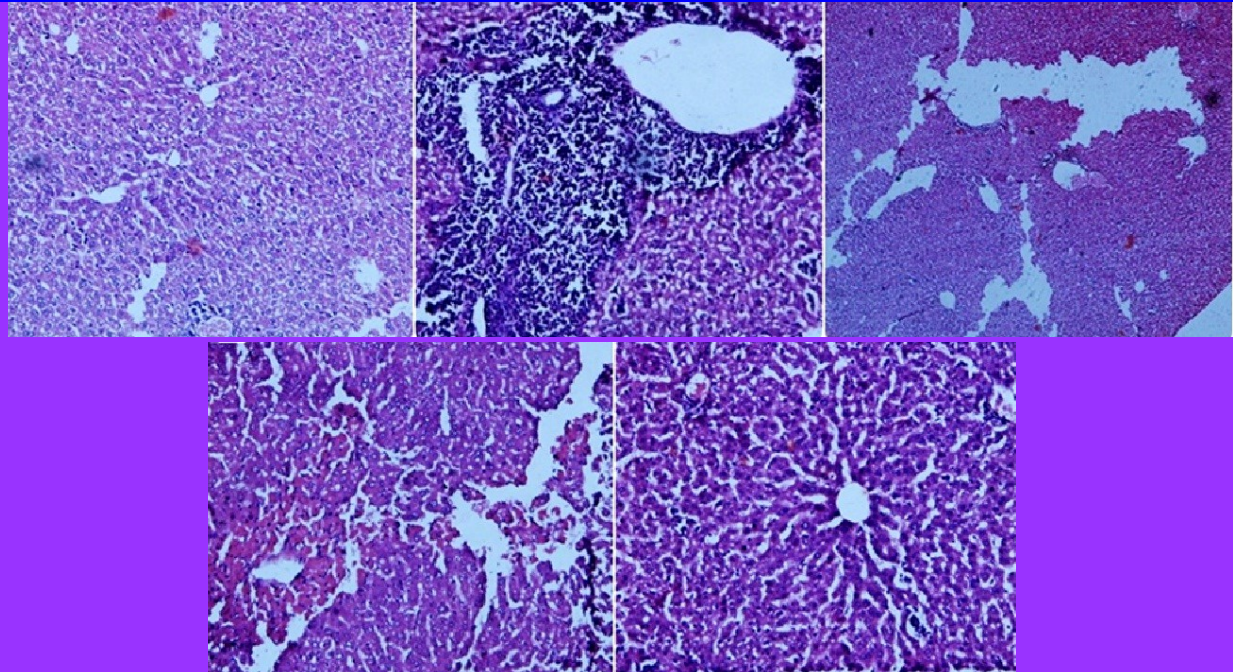

BJP

Bangladesh Journal of Pharmacology

Research Article

Hepatoprotective effect of *Chenopodium murale* in mice

Hepatoprotective effect of *Chenopodium murale* in mice

Mohammad Saleem¹, Bilal Ahmed¹, M. Imran Qadir¹, Mahrukh¹, Maria Rafiq¹, Mubasher Ahmad² and Bashir Ahmad³

¹College of Pharmacy, GC University Faisalabad, Faisalabad, Pakistan; ²University College of Pharmacy, University of the Punjab, Lahore, Pakistan; ³Faculty of Pharmacy, The University of Lahore, Lahore, Pakistan.

Article Info

Received: 29 January 2014

Accepted: 6 March 2014

Available Online: 10 March 2014

DOI: 10.3329/bjp.v9i1.17785

Cite this article:

Saleem M, Ahmed B, Qadir MI, Mahrukh, Rafiq M, Ahmad M, Ahmad B. Hepatoprotective effect of *Chenopodium murale* in mice. Bangladesh J Pharmacol. 2014; 9: 124-28.

Abstract

Discovery of drugs has its roots in medicinal plants that appeal researchers to identify new therapeutical entities from plants. The current study was conducted to determine its hepatoprotective activity. The results showed that aqueous methanolic extract of *Chenopodium murale* (200 and 500 mg/kg) produced significant ($p < 0.001$) decrease in paracetamol induced increased levels of liver enzymes (alanin transaminase, aspartate transaminase, alkaline phosphatase) and total bilirubin. These findings were further supported by histopathological investigations by microscope and detection of phyto-constituents having hepatoprotective potential e.g. quercetin, kaempferol and gallic acid by HPLC. Conclusively aqueous methanolic extract of *C. murale* possess hepatoprotective activity against paracetamol induced liver damage in mice.

Introduction

Liver is a crucial organ of our body having vital role in metabolism and elimination of various agents. Chemical agents pass through liver before entry to blood. So liver is at high risk of damage than other body organ (Samuel et al., 2012). Liver detoxify all toxins absorbed through gut but these toxins may harm to liver. That's why liver damage found one of the major disease in the world (Ravikumar et al., 2012). Drugs, xenobiotics, viral infections, alcohol and other chemical agents may damage the liver. The injury to liver is characterized by hepatic necrosis and lipid per-oxidation resulting in elevated levels of liver enzymes and bilirubin (Ramachandra et al., 2007).

Liver diseases like hepatitis, liver cirrhosis and fatty liver are very common and problematic. Drugs used for the treatment, like colchicines, interferon, corticosteroids and penicillamine have been found to possess various side effects. So, there is a dire need to develop some effective therapeutic agents from plant source to support liver function and to treat liver diseases having low incidence of side effects. The plants like *Luminetzer*

racemosa (Gnanadesigan et al., 2011), *Convolvulus arvensis* (Ali et al., 2013), *Hibiscus vitifolius* (Sameul et al., 2012), *Carica papaya* (Sadeque and Begum, 2010), *Carissa spinarum* (Hegde and Joshi, 2010), *Cocculus hirsutus* (Thakare et al., 2009), *Convolvulus arvensis* (Ali et al., 2013), *Dodonaea viscosa* (Khan et al., 2013), Khamira Gaozaban Ambri Jadwar Ood Saleeb Wala (Akhtar et al., 2013), *Oflpomoea staphylyna* (Bag and Mumtaz, 2013), *Suaeda fruticosa* (Rehman et al., 2013), *Trianthema decandra* (Balamurugan and Muthusamy, 2008) and *Trichodesma sedgwickianum* (Saboo et al., 2013) showed hepatoprotective effect.

In the present study *Chenopodium murale* was selected to evaluate its hepatoprotective potential. Previous studies regarding *C. murale* have shown that it possess anti-inflammatory, analgesics (Ibrahim et al., 2007), antifungal (Javaid et al., 2009), antibacterial (Ali et al., 2001) and hypotensive effects (Gohara and Elmazar, 1997). *C. album* the plant of this genus showed hepatoprotective action (Pal et al., 2011; Vijay and Padma, 2011).

C. murale contains flavanoids, saponins and terpenoids (Abbas et al., 2012) and has been proved to be antioxi-



dant (Ali et al., 2001). The presence of flavonoids (Vijay and Padmaa, 2011), saponins, (Kumar et al., 2011) or triterpenoids (Kim et al., 2004) is believed to be hepatoprotective. The detection of flavonoids in aqueous methanolic extract of *Chenopodium* in the current study and its previous findings, give us a clue for its hepatoprotective activity.

Material and Methods

Collection of plants: Fresh plants were collected from district Sialkot, Punjab Pakistan. Plant was identified by Dr. Mansoor Hameed, Department of Botany, University of Agriculture, Faisalabad. Vouchers No 531-2-13 can be used for future reference.

Preparation of plant extracts: Plant was washed, dried under shade and finally grounded to powder. The powdered plant was soaked in aqueous methanolic (30:70) solvent for 7 days with occasional shaking at regular intervals. The extract was filtered and evaporated by using rotary evaporator at 60°C. The residue was stored in amber coloured glass bottle at 4°C.

Experimental animals: Adult Swiss albino mice weighing about 22-34 g were used. All the animals were placed in the animal house of College of Pharmacy, GC University Faisalabad. The animals were allowed to acclimate under standard laboratory conditions prior to perform experiment.

Experimental protocol: All animals were divided into 5 groups containing 5 animals each. Group 1 served as control group receiving distilled water only Group II served as paracetamol control group received paracetamol 250 mg/kg (p.o) 7 days. Group III was treated with silymarin 50 mg/kg (p.o) and followed by paracetamol administration 3 hours after silymarin for 7 days. Group IV was treated with aqueous methanolic extract of *C. murale* at dose of 250 mg/kg (p.o) followed by paracetamol administration 250 mg/kg (p.o) 3 hours after the extract dose for 7 days. Group V was treated with aqueous methanolic extract of *C. murale* at dose of 500 mg/kg (p.o) followed by paracetamol administration 250 mg/kg (p.o) 3 hours after the extract dose for 7 days (Ali et al., 2013).

Biochemical and istopathological investigations: On 8th day, animals were sacrificed and blood was collected for serum separation. The change in aspartate aminotrans-

ferase (AST), alanine amino transferase (ALT), alkaline phosphatase (ALP) and total bilirubin (TB) levels were measured for biochemical investigations. Histopathological studies were also conducted to examine microscopic changes in liver architecture (Ali et al., 2013).

Histopathological examination: Histopathological study was carried out to see the microscopic changes in the hepatocytes. For this purpose the slides of the liver sections were prepared and were examined by microscope to see the changes in liver hepatocytes.

Identification of active constituents by HPLC: Qualitative determination of active constituents having hepatoprotective activity was done by using HPLC. Sample was prepared by adding small amount of extract in 5 mL distilled water, 12 mL methanol and kept for 5 min. Then 6 mL distilled water was again added and kept for 5 min. 10 mL of 15 M HCl was added and placed in oven for 2 hours. Final solution was filtered with syringe filter. Phenolics were separated using a shim-pack CLC-ODS (C-18) column, 25 cm × 4.6 mm, 5 μm. Mobile phase used was isocratic: ACN : dichloromethane: methanol-60:20:20 at a flow rate of 1 mL/min. Samples were analysed using UV-visible detector at 280 nm at room temperature while Kaempferol was separated at 248 nm (Sultana et al., 2008).

Statistical analysis: Statistical analysis was done with one-way ANOVA (analysis of variance). Results were showed by Mean ± SE.

Results

The average value of ALT of normal animals was 50.2 ± 3.0 (Table I). Treatment with paracetamol raised this value to 172.4 ± 6.2. Administration of aqueous methanolic extract of *C. murale* at dose of 250 and 500 mg/kg brought the level of this enzyme to 92.8 ± 13.5 and 72.2 ± 14.4 respectively which is comparable to (p>0.001) standard hepatoprotective drug, silymarin 61 ± 6.1. The average value of AST of normal animals was 57.8 ± 3.4. Treatment with paracetamol raised this value to 167.4 ± 6.5. Administration of aqueous methanolic extract of *C. murale* at dose of 250 and 500 mg/kg brought the level of this enzyme to 90.6 ± 10.3 and 73.4 ± 10.6 respectively which is comparable to (p>0.001) standard hepatoprotective drug, silymarin 68.8 ± 2.8. The average value of ALP of normal animals was 173.6 ± 16.2. Treatment

	ALT (U/L)	AST (U/L)	ALP (U/L)	TB (mg/dL)
Normal	50.2 ± 3.0	57.8 ± 3.4	173.6 ± 16.2	0.7 ± 0.03
Paracetamol control 250 mg/kg	172.4 ± 6.2	167.4 ± 6.5	407.6 ± 36.4	2.0 ± 0.2
Silymarin 50 mg/kg + PCM 250 mg/kg	61.0 ± 6.1 ^b	68.8 ± 2.8 ^b	190.4 ± 12.4 ^b	0.8 ± 0.02 ^b
Extract 250 mg/kg + PCM 250 mg/kg	92.8 ± 13.5 ^b	90.6 ± 10.3 ^b	220.2 ± 9.3 ^a	0.9 ± 0.1 ^b
Extract 500 mg/kg + PCM 250 mg/kg	72.2 ± 14.4 ^b	73.4 ± 10.6 ^b	197.2 ± 17.6 ^b	0.7 ± 0.04 ^b

Mean ± S.E; ^ap<0.01; ^bp<0.001

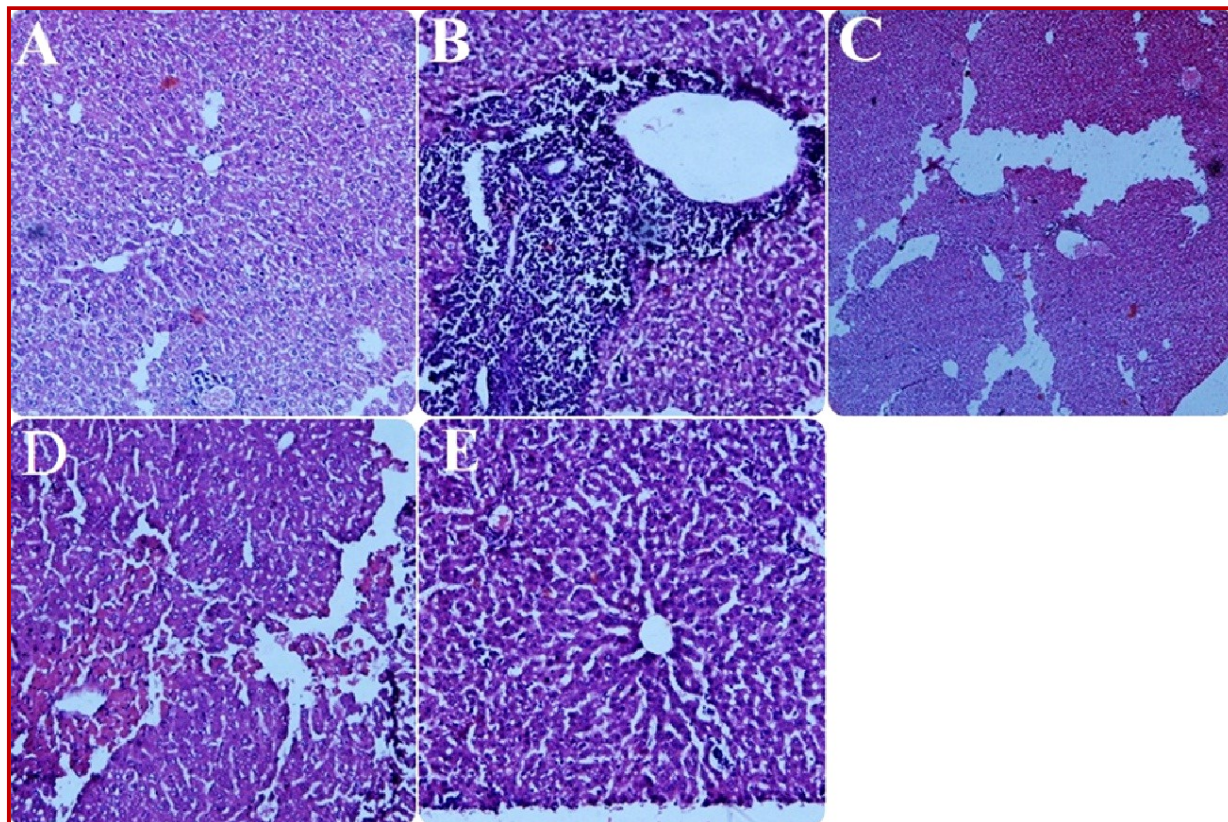


Figure 1: (A) Normal hepatocytes; (B) PCM treated; (C) Silymarin treated; (D) *C. murale* 250 mg/kg treated; (E) *C. murale* 500 mg/kg treated

with paracetamol raised this value to 407.6 ± 36.4 . Administration of aqueous methanolic extract of *C. murale* at dose of 250 and 500 mg/kg brought the level of this enzyme to 220.2 ± 9.3 and 197.2 ± 17.6 respectively which is comparable to ($p > 0.001$) silymarin 190.4 ± 12.4 . Similarly the average value of total bilirubin of normal animals was 0.72 ± 0.03 . Treatment with paracetamol raised this value to 2.0 ± 0.2 . Administration of aqueous methanolic extract of *C. murale* at dose of 250 and 500 mg/kg brought the level of this enzyme to 0.9 ± 0.1 and 0.7 ± 0.04 respectively which is comparable to ($p > 0.001$) silymarin 0.8 ± 0.02 .

Histopathology studies showed that the liver architecture was normal in the control group (Figure 1). While the PCM-treated group showed the severe periportal inflammation, tissue necrosis, ballooning and dilation in sinusoidal spaces. Silymarin-treated group showed only mild inflammation with no ballooning. Animals treated with aqueous methanolic extract of *C. murale* also showed mild inflammation with no ballooning.

HPLC analysis of aqueous methanolic extract of *C. murale* indicated the presence of quercetin, gallic acid, chlorogenic acid, *p*-coumaric acid, sinapic acid and kaempferol (Figure 2). Among which quercetin, gallic acid and kaempferol are hepatoprotective, the chemical structures are shown in Figure 3.

Discussion

In present study aqueous methanolic extracts of *C. murale* were studied at two concentrations. Results were almost similar at both concentrations. Aqueous methanolic extract decreased the elevated level of ALT, AST, ALP and bilirubin as compared to control group. *C. murale* contains flavonoids, saponins and terpenoids (Abbas et al., 2012). Hepatoprotective properties of a plant may be due to the presence of flavonoids (Vijay and Padmaa, 2011), saponins, (Kumar et al., 2011) or triterpenoids (Kim et al., 2004). *C. murale* also contain β -Sitosterol and Stigmasterol (Ahmad et al., 2003) which showed antihepatotoxic action (Patra et al., 2009). Stigmasterol caused decrease in lipid peroxidation in liver and increase in CAT, SOD and GSH activities (Panda et al., 2009). The plant also contained heat stable SOD enzyme which give protection against oxidative stress (Khanna-Chopra et al., 2004).

Previous studies have indicated that quercetin (Janbaz et al., 2004; Rasheed et al., 2013) and kaempferol (Adewusi and Afolayan, 2010) and gallic acid (Jadon et al., 2007) have hepatoprotective activity. In the current study HPLC analysis showed the presence of quercetin, Kaempferol, and gallic acid so it seems that this protection of liver by aqueous methanolic extract of *C. murale* may be due to presence of these hepatopro-

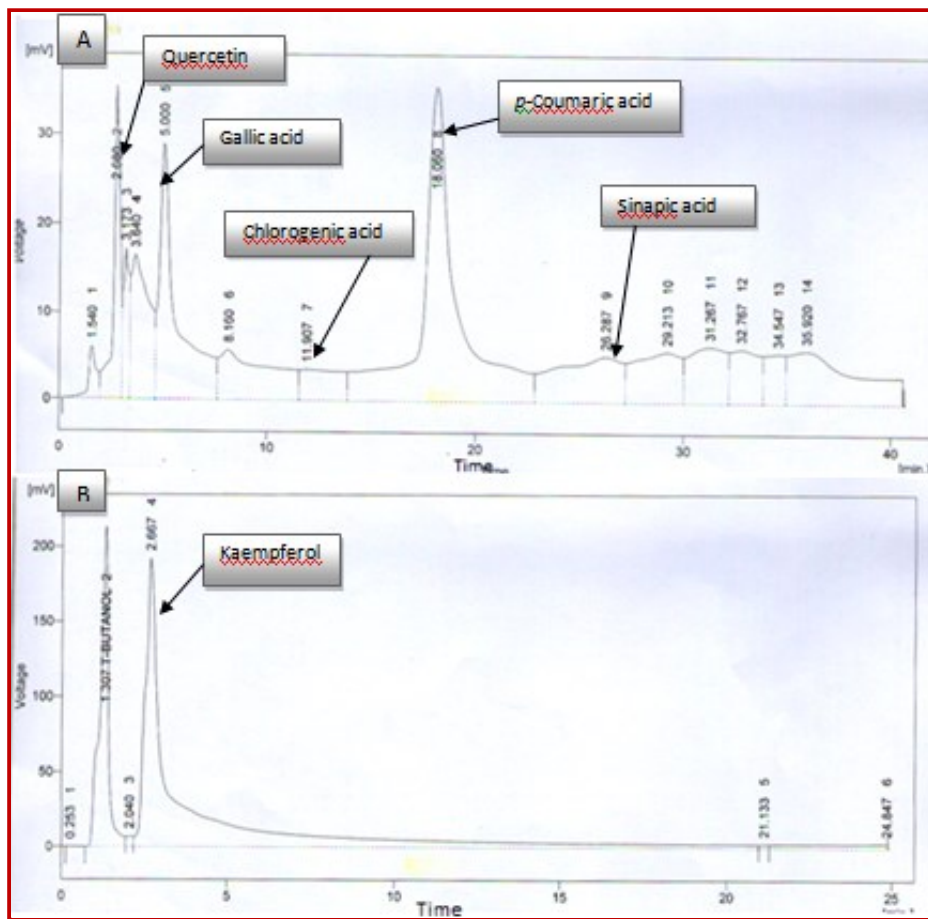


Figure 2: HPLC analysis of aqueous methanolic extract of *C. murale*. A) Detection at 280 nm; B) Detection at 248 nm

tective constituents. Our findings suggest that aqueous methanolic extract of *C. murale* is hepatoprotective against paracetamol induced liver injury in mice.

References

- Abbas M, Rana S, Shahid M, Rana N, Mahmood-ul-Hassan M, Hussain M. Chemical evaluation of weed seeds mixed with wheat grains at harvest. *J Animal Plant Sci.* 2012; 22: 283-88.
- Adewusi E, Afolayan A. A review of natural products with hepatoprotective activity. *J Medicinal Plants Res.* 2010; 4: 1318-34.
- Ahmad B, Jan Q, Bashir S, Choudhary MI, Nisar M. Phytochemical evaluation of *Chenopodium murale* Linn. *Asian J Plant Sci.* 2003; 3: 1072-78.
- Akhtar MS, Asjad HMM, Bashir S, Malik A, Khalid R, Gulzar F, Irshad N. Evaluation of anti-oxidant and hepatoprotective effects of Khamira Gaozaban Ambri Jadwar Ood Saleeb Wala (KGA). *Bangladesh J Pharmacol.* 2013; 8: 44-48.
- Ali M, Qadir MI, Saleem M, Janbaz KH, Gul H, Hussain L,

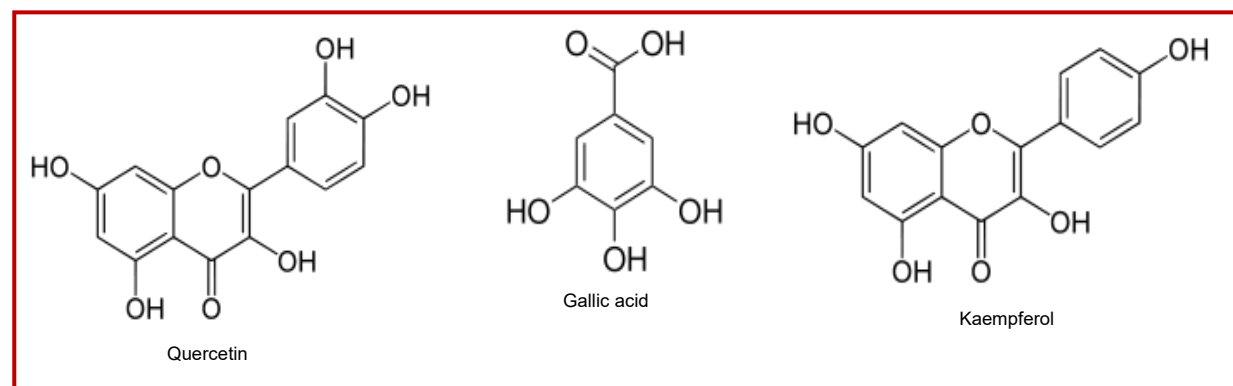


Figure 3: Hepatoprotective constituents of *C. murale*

- Ahmad B. Hepatoprotective potential of *Convolvulus arvensis* against paracetamol-induced hepatotoxicity. *Bangladesh J Pharmacol.* 2013; 8: 300-04.
- Ali M, Qadir MI, Saleem M, Janbaz KH, Gul H, Hussain L, Ahmad B. Hepatoprotective potential of *Convolvulus arvensis* against paracetamol-induced hepatotoxicity. *Bangladesh J Pharmacol.* 2013; 8: 300-04.
- Ali N, Jülich WD, Kusnick C, Lindequist U. Screening of Yemeni medicinal plants for antibacterial and cytotoxic activities. *J Ethnopharmacol.* 2001; 74: 173-79.
- Bag AK, Mumtaz SMF. Hepatoprotective and nephroprotective activity of hydroalcoholic extract *Oflpomoea staphylinina* leaves. *Bangladesh J Pharmacol.* 2013; 8: 263-68.
- Balamurugan G, Muthusamy P. Observation of the hepatoprotective and antioxidant activities of *Trianthema decandra* Linn. (Vallai sharunnai) roots on carbon tetrachloride-treated rats. *Bangladesh J Pharmacol.* 2008; 3: 83-89.
- El-Khatib AA, Hegazy AK, Galal HK. Does allelopathy have a role in the ecology of *Chenopodium murale*? *Ann Bot Fennici.* 2004; 41: 37-45.
- Gnanadesigan M, Ravikumar S, Inbaneson SJ. Hepatoprotective and anti-oxidant properties of marine halophyte *Luminetzera racemosa* bark extract in CCL₄-induced hepatotoxicity. *Asian Pac J Trop Med.* 2011; 4: 462-465
- Gohara AA, Elmazar M. Isolation of hypotensive flavonoids from *Chenopodium* species growing in Egypt. *Phytother Res.* 1997; 11: 564-67.
- Hegde K, Joshi AB. Hepatoprotective and antioxidant effect of *Carissa spinarum* root extract against CCL₄ and paracetamol-induced hepatic damage in rats. *Bangladesh J Pharmacol.* 2010; 5: 73-76.
- Ibrahim L, Kawashty S, Baiuomy AR, Shabana M, El-Eraky W, El-Negoumy S. A comparative study of the flavonoids and some biological activities of two *Chenopodium* species. *Chem Nat Compd.* 2007; 43: 24-28.
- Jadon A, Bhadauria M, Shukla S. Protective effect of *Terminalia bellerica* Roxb and gallic acid against carbon tetra-chloride-induced damage in albino rats. *J Ethnopharmacol.* 2007; 109: 214-18.
- Janbaz K, Saeed S, Gilani A. Studies on the protective effects of caffeic acid and quercetin on chemical-induced hepatotoxicity in rodents. *Phytomedicine* 2004; 11: 424-30.
- Javaid A, Amin M. Antifungal activity of methanol and n-hexane extracts of three *Chenopodium* species against *Macrophomina phaseolina*. *Nat Prod Res.* 2009; 23: 1120-27.
- Khanna-Chopra R, Sabarinath S. Heat-stable chloroplastic Cu/Zn superoxide dismutase in *Chenopodium murale*. *Biochem Biophys Res Commun.* 2004; 320: 1187-92.
- Khan AZ, Mohammad A, Iqbal Z, Anis I, Shah MR, Nadeem S, Rabnawaz M, Shahidullah A, Khan H, Khan I. Molecular docking of viscocine as a new lipoxigenase inhibitor isolated from *Dodonaea viscosa*. *Bangladesh J Pharmacol.* 2013; 8: 36-39.
- Kim KA, Lee JS, Park HJ, Kim JW, Kim CJ, Shim IS et al. Inhibition of cytochrome P450 activities by oleanolic acid and ursolic acid in human liver microsomes. *Life Sci.* 2004; 74: 2769-79.
- Kumar B, Lakshman K, Swamy V, Kumar P, Shekar D, Manoj B, Vishwantha G. Hepatoprotective and anti-oxidant activities of *Amaranthus viridis* Linn. *Macedonian J Med Sci.* 2011; 4: 125-30
- Mitić N, Dmirović S, Djordjević M, Zdravković-Korać S, Nikolić R, Raspor M, Krstić-Milošević D. Use of *Chenopodium murale* L. transgenic hairy root *in vitro* culture system as a new tool for allelopathic assays. *J Plant Physiol.* 2012; 169: 1203-11.
- Pal A, Banerjee B, Banerjee T, Masih M, Pal K. Hepatoprotective activity of *Chenopodium album* Linn. plant against paracetamol induced hepatic injury in rats. *Int J Pharm Pharm Sci.* 2011; 3: 55-57.
- Panda S, Jafri M, Kar A, Meheta B. Thyroid inhibitory, anti-peroxidative and hypoglycemic effects of stigmasterol isolated from *Butea monosperma*. *Fitoterapia* 2009; 80: 123-26.
- Patra A, Jha S, Murthy PN. Phytochemical and pharmacological potential of *Hygrophila spinosa* T. anders. *Pharmacogn Rev.* 2009; 3: 330-41.
- Ramachandra SS, Quereshi AA, Viswanath SA, Patil T, Prakash T, Prabhu K, Veeran GA. Hepatoprotective activity of *Calotropis procera* flowers against paracetamol-induced hepatic injury in rats. *Fitoterapia* 2007; 78: 451-54.
- Rashed KN, Chang CW, Wu LY, Peng WH. Hepatoprotective activity of *Diospyros lotus* fruits on acute liver injury induced by carbon tetrachloride and phytochemical analysis. *Topcls J Herb Med.* 2013; 2: 75-83.
- Ravikumar S, Gnanadesigan M. Hepatoprotective and antioxidant properties of *Rhizophora mucronata* Mangrove Plant in CCL₄ Intoxicated Rats. *J Exp Clin Med.* 2012; 4: 66-72.
- Rehman JU, Saqib NU, Akhtar N, Jamshaid M, Asif HM, Sultana S, Rehman RU. Hepatoprotective activity of aqueous-methanolic extract of *Suaeda fruticosa* in paracetamol-induced hepatotoxicity in rabbits. *Bangladesh J Pharmacol.* 2013; 8: 378-81.
- Saboo SS, Tapadiya G, Farooqui IA, Khadabadi SS. Free radical scavenging, *in vivo* anti-oxidant and hepatoprotective activity of folk medicine *Trichodesma sedgwickianum*. *Bangladesh J Pharmacol.* 2013; 8: 58-64.
- Sadeque MZ, Begum ZA. Protective effect of dried fruits of *Carica papaya* on hepatotoxicity in rat. *Bangladesh J Pharmacol.* 2010; 5: 48-50.
- Samuel AJSJ, Mohan S, Chellappan DK, Kalusalingam A, Ariamuthu S. *Hibiscus vitifolius* (Linn.) root extracts shows potent protective action against anti-tubercular drug induced hepatotoxicity. *J Ethnopharmacol.* 2012; 141: 396-402.
- Sultana B, Anwar F, Rafique AM, Chatha SAH. Anti-oxidant potential of extracts from different agro wastes: Stabilization of corn oil. *Grasas Y Aceites.* 2008; 59: 205-17.
- Thakare SP, Jain HN, Patil SD, Upadhyay UM. Hepatoprotective effect of *Cocculus hirsutus* on bile duct ligation-induced liver fibrosis in albino Wistar rats. *Bangladesh J Pharmacol.* 2009; 4: 126-30.
- Vijay N, Padmaa M. Hepatoprotective activity of *Chenopodium album* Linn. against paracetamol induced liver damage. *Pharmacologyonline* 2011; 3: 312-28.

Author Info

Mohammad Saleem (Principal contact)
e-mail: saleem2978@hotmail.com