



BJP

Bangladesh Journal of Pharmacology

Research Article

Hepatoprotective activity of aqueous methanolic extract of *Viola odorata* against paracetamol-induced liver injury in mice

Hepatoprotective activity of aqueous methanolic extract of *Viola odorata* against paracetamol-induced liver injury in mice

M. Imran Qadir¹, Muhammad Ali¹, Muhammad Ali², Mohammad Saleem¹ and Muhammad Hanif³

¹College of Pharmacy, GC University, Faisalabad, Pakistan; ²Institute of Molecular Biology & Biotechnology, Bahauddin Zakariya University, Multan, Pakistan; ³Faculty of Pharmacy, Bahauddin Zakariya University, Multan, Pakistan.

Article Info

Received: 19 February 2014
Accepted: 28 February 2014
Available Online: 25 April 2014
DOI: 10.3329/bjp.v9i2.18049

Cite this article:

Qadir MI, Ali M, Ali M, Saleem M, Hanif M. Hepatoprotective activity of aqueous methanolic extract of *Viola odorata* against paracetamol-induced liver injury in mice. Bangladesh J Pharmacol. 2014; 9: 198-202.

Abstract

Traditionally *Viola odorata* is used for liver protection. To provide scientific support to its traditional use, aqueous methanolic extract of *V. odorata* (250 and 500 mg/kg) was given to mice intoxicated with paracetamol. Obtained results demonstrated that the extract significantly ($p < 0.01-0.001$) reduced paracetamol induced increase levels of serum hepatic enzymes and total bilirubin. Histopathological studies showed that the plant attenuated the hepatocellular necrosis and inflammation. HPLC results showed the presence of hepatoprotective flavonoids (isorhamnetin and luteolin) in the extract. It was concluded from the present study that *V. odorata* has hepatoprotective activity against paracetamol-induced liver injury in mice.

Introduction

Now-a-days, liver diseases are one of the major issues of all the medical community due to the higher rate of mortality and morbidity. There are lot of medicines and natural plants available in commercial market for liver diseases. These products do not cure all the liver symptoms. Therefore, there is a need to find out the perfect remedy. Many plants have been identified as hepatoprotective like *Trianthema decandra* (Balamurugan and Muthusamy, 2008), *Cocculus hirsutus* (Thakare et al., 2009), *Carica papaya* (Sadeque and Begum, 2010), *Carissa spinarum* (Hegde and Joshi, 2010), *Convolvulus arvensis* (Ali et al., 2013), *Dodonaea viscosa* (Khan et al., 2013), *Trichodesma sedgwickianum* (Saboo et al., 2013), *Oflpomoea staphylina* (Bag and Mumtaz, 2013), Khamira Gaozaban Ambri Jadwar Ood Saleeb Wala (Akhtar et al., 2013) and *Morus nigra* (Mallhi et al., 2014).

Viola odorata L. (family Violaceae), commonly known as sweet violet or banafsheh, is cultivated in all over the world as an ornamental plant. Pharmacologically, it has

been reported that *V. odorata* has anti-inflammatory (Koochek et al., 2003), antipyretic (Khattak et al., 1985) and antibacterial activity (Arora and Kaur, 2007). Flavonoids have been identified in *V. odorata* (Siddiqi et al., 2012) and they may have hepatoprotective activity (Ali et al., 2013). Traditionally *V. odorata* is worthwhile to cure Jaundice (Amiri et al., 2014). Phytochemical profile and traditional use of *V. odorata* in liver injury appealed us to scientifically evaluate its hepatoprotective potential.

Materials and Methods

Plant material

Aerial parts of *V. odorata* were collected from Faisalabad (Pakistan) and identified from Department of Botany, University of Agriculture, Faisalabad, Pakistan. The plants were kept in herbarium for future reference. The plants were shade-dried and powdered by a mechanical grinder. The powdered material was extracted by the



method of cold maceration using aqueous methanol (70:30) as solvents. After soaking the powdered extract for 48 hours, it was passed through muslin cloth and then through filter paper for filtration. Rotary evaporator was used for concentrating the extracts.

Experimental animal

Swiss Albino mice weigh about 20-35 g were used. Mice obtained from the NIH Islamabad. The animals were kept in animal house of College of Pharmacy, housed in standard condition and feed with standard pellet diet and water *ad libitum* (Vadivu et al., 2008).

Experimental protocol

Animals were divided into five groups containing six animals each. Group I was control group received distilled water only. Group II received paracetamol at the dose of 250 mg/kg orally dissolved in water daily for 7 days. Group III was treated with silymarin as standard drug at the dose of 50 mg/kg p.o daily for 7 days and received paracetamol 3 hours after silymarin. Group IV was treated with 250 mg/kg p.o of aqueous methanolic extract of *V. odorata* for 7 days and received paracetamol 250 mg/kg p.o for 7 days 3 hours after the extract dose. Group V was treated with 500 mg/kg p.o aqueous methanolic extract of *V. odorata* for 7 days and received paracetamol 250 mg/kg p.o for 7 days 3 hours after the extract dose (Sabir and Rocha, 2008).

After completing the last dose mice sacrificed by cervical dislocation. By decapitate sedated mice we can draw the maximum Blood from mice and the blood was collected in eppendroff tubes and the clot was dispersed with glass rod and then centrifuged at 3000 rpm for 15 min. Then separated out the serum that was used to estimate SGPT, SGOT and serum alkaline phosphatase to present the parameter of LFT and serum total bilirubin used as excretory function test. The liver from animals was separated for histopathological studies (Ali et al., 2013).

Identification of active constituent by HPLC

Hepatoprotective activity may be due to flavonoids (Ali et al., 2013). HPLC may be used to separate and identify the flavonoids. HPLC protocol was used as described elsewhere (Saddiqe et al., 2011). By using the said protocol, retention time for quercetin is 2.05, myricetin 1.75, isorhamnetin 2.72, kaepferol 2.6, luteolin 1.98.

Statistical analysis

One-way ANOVA (analysis of variance) was used for statistical analysis. Results were represented by mean \pm SE.

Results

Serum biochemical parameters are shown in Table I. Paracetamol administration caused damage to hepatocytes demonstrated by raised level of liver enzymes (ALT, AST and ALP) and total bilirubin as compared to control. Elevated levels of these enzymes are indicative of cellular damage and loss of functional integrity of hepatocytes. *V. odorata* pretreatment significantly restored elevated levels of ALT with 250 and 500 mg/kg ($p < 0.01$), AST with 250 and 500 mg/kg ($p < 0.01$), ALP with 250 mg/kg ($p < 0.01$) and with 500 mg/kg ($p < 0.001$) and total bilirubin with 250 mg/kg ($p < 0.01$) and with 500 mg/kg ($p < 0.001$). Both doses (250 mg/kg and 500 mg/kg) provided significant approximately similar reduction in biochemical parameters except ALP and total bilirubin. Results for histopathological examination are given in Figure 1. The normal (control) group receiving distilled water only has normal nuclei. While the administration of paracetamol causes necrosis, inflammation and ballooning of cells. The group treated with silymarin has mild inflammation and necrosis and ballooning was also absent. The groups treated with both doses (D, E) of *V. odorata* have few inflammatory cells but most of the cells gained normal structures as were present in control group (A).

Phytochemical analysis for qualitative determination of

Table I

Effect of aqueous methanolic extract of *Viola odorata* on liver enzymes and total bilirubin

| Treatment groups | ALT (U/L) | AST (U/L) | ALP (U/L) | Total bilirubin (g/dL) |
|---|-----------------------------|-----------------------------|-------------------------------|----------------------------|
| Normal (control) | 44.0 \pm 2.7 | 62.8 \pm 3.0 | 218.0 \pm 8.3 | 0.7 \pm 0.0 |
| Paracetamol (250 mg/kg) | 134.5 \pm 12.1 | 90.5 \pm 5.2 | 325.0 \pm 12.6 | 1.6 \pm 0.1 |
| Silymarin 50 mg/kg + paracetamol (250 mg/kg) | 47.3 \pm 4.0 ^b | 44.8 \pm 3.6 ^b | 172.3 \pm 18.1 ^b | 0.7 \pm 0.0 ^b |
| Extract (250 mg/kg) + paracetamol (250 mg/kg) | 81.0 \pm 6.3 ^a | 65.8 \pm 3.6 ^a | 287.8 \pm 11.1 ^a | 0.8 \pm 0.0 ^a |
| Extract (500 mg/kg) + paracetamol (250 mg/kg) | 57.8 \pm 3.6 ^a | 58.8 \pm 4.2 ^a | 205.8 \pm 8.9 ^b | 0.8 \pm 0.0 ^b |

Data are mean \pm SE; ^a $p < 0.01$; ^b $p < 0.001$

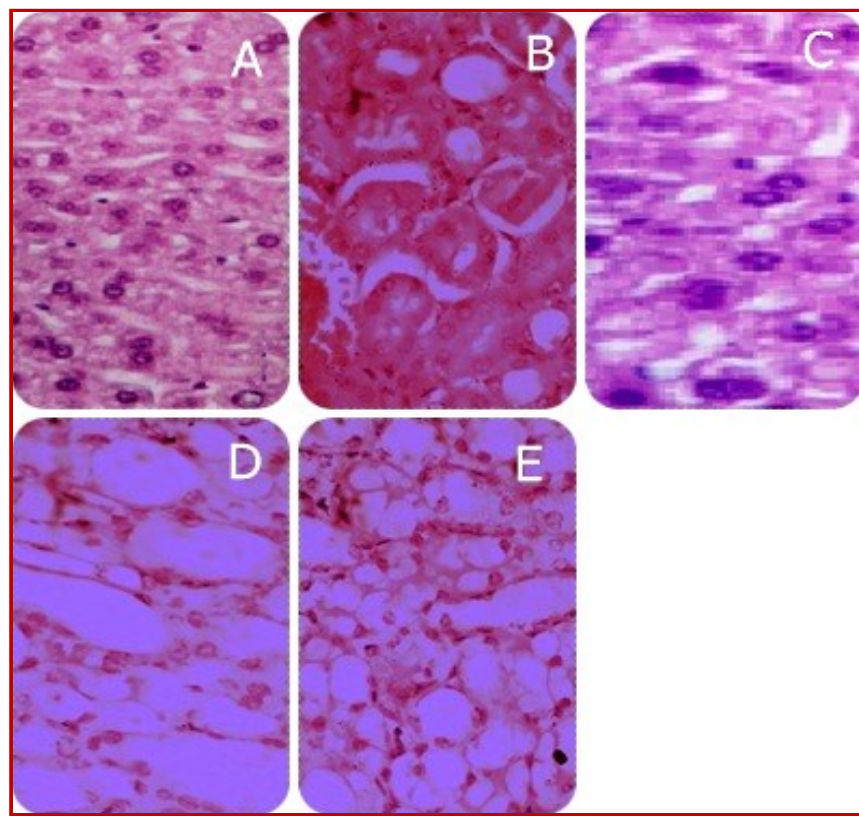


Figure 1: Histopathological pictures of (A) normal hepatocytes, (B) paracetamol-treated, (C) silymarin-treated, (D) 250 mg/kg extract treated, (E) 500 mg/kg extract treated

active constituents through HPLC showed presence of two flavonoids: isorhamnetin and luteolin (Figure 2).

Discussion

The liver is the major organ of the body and metabolizes many nutrients carbohydrates, proteins, lipids; and also metabolize the drugs, and excrete them from the body (Saleem et al., 2010). Many drugs and chemicals cause the damage to the liver. The existing hepatoprotective drugs are not full of the efficacy. Efficacy of a drug may be increased by increasing the drug delivery to the target site by the use of polymers (Khalid et al., 2009; Hussain et al., 2011) or through

nanotechnology (Naz et al., 2012; Ehsan et al., 2012), synthesis of new drugs, either by the use of proteomics (Qadir, 2011), or synthesis from lactic acid bacteria (Masood et al., 2011), or marine microorganisms (Javed et al., 2011). However, now-a-days, the trend is also being changed to the use of herbal products for their use as their anti-inflammatory (Qadir, 2009), hypotensive (Qadir, 2010), hypoglycaemic (Qadir and Malik, 2009; Qadir and Malik, 2010), amoebicidal (Asif and Qadir, 2011), anti-fertility, cytotoxic, antibiotic (Amin et al., 2012), spasmolytic, bronchodilator (Janbaz et al., 2013), anti-oxidant (Janbaz et al., 2012) and hepatoprotective (Ahmad et al., 2012).

V. odorata was considered to be a hepatoprotective traditionally (Amiri et al., 2014), which was proven by

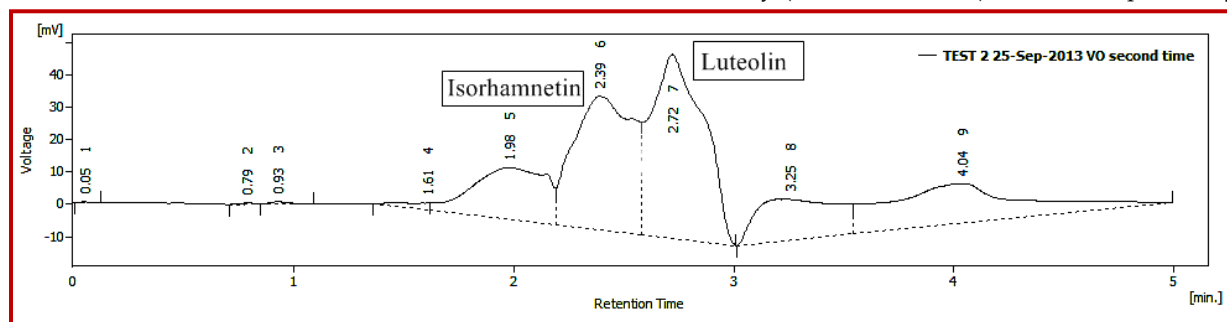


Figure 2: HPLC chromatogram of aqueous methanolic extract of *Viola odorata*

this study. Results showed that paracetamol damages the liver but after taking standard hepatoprotective drug (silymarin), liver cells cured. Mice which treated with *V. odorata* were also looking healthy but the results were less significant than the silymarin. Significant reduction ($p < 0.01$) of biochemical markers was observed with aqueous methanolic extract of *V. odorata* in paracetamol-treated mice. Two doses (250 and 500 mg/kg) were screened to evaluate hepatoprotective potential of this plant. There were no significant difference ($p > 0.05$) between two doses in terms of liver enzymes e.g. ALT, AST and ALP. This is indicative that *V. odorata* doesn't cause dose-dependent reduction of liver enzymes. On the other hand, the two doses have significant difference ($p < 0.01$) when compared each other for reduction of total bilirubin. Direct proportion relationship of dose-response can be confirmed by more focused studies.

The biochemical results were further supported by histopathological findings. Paracetamol administration lead to damages normal hepatocyte's structure that were restored with silymarin. Similar effects were observed with plant extract showing improvement in inflammation-necrosis score and reversal of normal hepatocytes.

Results were further supported by HPLC, in which two flavonoids were found isorhamnetin and luteolin. These flavonoids belong to flavonols class which is well reported to have hepatoprotective activity (Singab et al., 2005; Chattopadhyay et al., 2003).

Conclusion

V. odorata has hepatoprotective activity against paracetamol-induced liver injury in mice.

Financial Support

Self-funded

Ethical Issue

The study was approved by the local Ethical Committee

Conflict of Interest

Authors declare no conflict of interest

Acknowledgements

Authors are thankful to Mr. Asif Masud and Mr. Bilal Ahmed for their contribution to accomplish this study.

References

- Ahmad M, Mahmood Q, Gulzar K, Akhtar MS, Saleem M, Qadir MI. Antihyperlipidaemic and hepatoprotective activity of *Dodonaea viscosa* leaves extracts in alloxan-induced diabetic rabbits (*Oryctolagus cuniculus*). Pakistan Vet J. 2012; 32: 50-54.
- Akhtar MS, Asjad HMM, Bashir S, Malik A, Khalid R, Gulzar F, Irshad N. Evaluation of antioxidant and hepatoprotective effects of Khamira Gaozaban Ambri Jadwar Ood Saleeb Wala (KGA). Bangladesh J Pharmacol. 2013; 8: 44-48.
- Ali M, Qadir MI, Saleem M, Janbaz KH, Gul H, Hussain L, Ahmed B. Hepatoprotective potential of *Convolvulus arvensis* against paracetamol-induced hepatotoxicity. Bangladesh J Pharmacol. 2013; 8: 300-04.
- Amin N, Qadir MI, Khan TJ, Abbas G, Ahmad B, Janbaz KH, Ali M. Antibacterial activity of Vacuum liquid chromatography (VLC) isolated fractions of chloroform extracts of seeds of *Achyranthes aspera*. J Chem Soc Pak. 2012; 34: 589-92.
- Amiri MS, Joharchi MR, Taghavizadeh Yazdi ME. Ethnomedicinal plants used to cure jaundice by traditional healers of Mashhad, Iran. Iranian J Pharm Res. 2014; (Ahead of print)
- Arora DS, Kaur GJ. Antibacterial activity of some Indian medicinal plants. Natl Med J. 2007; 61: 313-17.
- Asif MA, Qadir MI. Molecular approaches for development of malarial vaccines. Rev Pharmacol. 2011; 4: 276-78.
- Bag AK, Mumtaz SMF. Hepatoprotective and nephroprotective activity of hydroalcoholic extract *OfIpomoea staphylina* leaves. Bangladesh J Pharmacol. 2013; 8: 263-68.
- Balamurugan G, Muthusamy P. Observation of the hepatoprotective and anti-oxidant activities of *Trianthema decandra* Linn. (Vallai sharunnai) roots on carbon tetrachloridetreated rats. Bangladesh J Pharmacol. 2008; 3: 83-89.
- Chattopadhyay RR. Possible mechanism of hepatoprotective activity of *Azadirachta indica* leaf extract. J Ethnopharmacol. 2003; 89: 217-19.
- Ehsan O, Qadir MI, Malik SA, Abbassi WS, Ahmad B. Efficacy of nanogold-insulin as a hypoglycemic agent. J Chem Soc Pakistan. 2012; 34: 365-70.
- Hegde K, Joshi AB. Hepatoprotective and antioxidant effect of *Carissa spinarum* root extract against CCl₄ and paracetamol-induced hepatic damage in rats. Bangladesh J Pharmacol. 2010; 5: 73-76.
- Hussain A, Khalid SH, Qadir MI, Massud A, Ali M, Khan IU, Saleem M, Iqbal MS, Asghar S, Gul H. Water uptake and drug release behaviour of methyl methacrylate-co-itaconic acid [P(MMA/IA)] hydrogels cross-linked with methylene bis-acrylamide. J Drug Deliv Sci Tech. 2011; 21: 249-55.
- Janbaz KH, Nisar U, Ashraf M, Qadir MI. Spasmolytic, broncho-dilator and anti-oxidant activities of *Erythrina superosa* Roxb. Acta Pol Pharm. 2012; 69: 1111-17.
- Janbaz KH, Saeed SA, Gilani, AH. Studies on the protective effects of caffeic acid and quercetin on chemical-induced hepatotoxicity in rodents. Phytomedicine 2004; 11: 424-30.

- Javed F, Qadir MI, Janbaz KH, Ali M. Novel drugs from marine microorganisms. *Cr Rev Microbiol*. 2011; 37: 245-49.
- Khalid SH, Qadir MI, Massud A, Ali M, Rasool MH. Effect of degree of cross-linking on swelling and drug release behaviour of poly (methyl methacrylate-co-itaconic acid) [P (MMA/IA)] hydrogels for site specific drug delivery. *J Drug Deliv Sci Tech*. 2009; 19: 413-18.
- Khan AZ, Mohammad A, Iqbal Z, Anis I, Shah MR, Nadeem S, Rabnawaz M, Shahidullah A, Khan H, Khan I. Molecular docking of viscosine as a new lipoxygenase inhibitor isolated from *Dodonaea viscosa*. *Bangladesh J Pharmacol*. 2013; 8: 36-39.
- Khattak SG, Gilani SN, Ikram M. Antipyretic studies on some indigenous Pakistani medicinal plants. *J Ethnopharmacol*. 1985; 14: 45-51.
- Koochek M, Pipelzadeh M, Mardani H. The effectiveness of *Viola odorata* in the prevention and treatment of formalin induced lung damage in the rat. *J Herbs Spices Med Plants*. 2003; 10: 95-103.
- Masood MI, Qadir MI, Shirazi JH, Khan IU. Beneficial effects of lactic acid bacteria on human beings. *Cr Rev Microbiol*. 2011; 37: 91-98.
- Naz S, Qadir MI, Ali M, Janbaz KH. Nanotechnology for imaging and drug delivery in cancer. *J Chem Soc Pakistan*. 2011; 34: 107-11.
- Qadir MI, Malik SA. Anti-diabetic activity of inorganic metals *Eugenia jambolana* Lam. (Myrtaceae) flowers. *Pharmacologyonline* 2010; 2: 979-85.
- Qadir MI, Malik SA. Effect of *Eugenia jambolana* leaves extracts on blood glucose levels of experimental diabetic rabbits. *Pharmacologyonline*. 2009; 3: 829-35.
- Qadir MI. Medicinal and cosmetological importance of *Aloe vera*. *Int J Nat Ther*. 2009; 2: 21-26.
- Qadir MI. Medicinal values of ginger. *Int J Nat Ther*. 2009; 3: 19-22.
- Qadir MI. Qadirvirtide. *Pakistan J Pharm Sci*. 2011; 24: 593-95.
- Sabir SM, Rocha JBT. Anti-oxidant and hepatoprotective activity of aqueous extract of *Solanum fastigiatum* against paracetamol-induced liver damage in mice. *J Ethnopharmacol*. 2008; 120: 226-32.
- Saboo SS, Tapadiya G, Farooqui IA, Khadabadi SS. Free radical scavenging, *in vivo* anti-oxidant and hepatoprotective activity of folk medicine *Trichodesma sedgwickianum*. *Bangladesh J Pharmacol*. 2013; 8: 58-64.
- Saddiqe Z, Naeem I, Maimoona A, Sautreau A, Hellio C. Assay of flavonoid aglycones with HPLC in four species of genus *Hypericum*. *J Med Plants Res*. 2011; 5: 1526-30.
- Sadeque MZ, Begum ZA. Protective effect of dried fruits of *Carica papaya* on hepatotoxicity in rat. *Bangladesh J Pharmacol*. 2010; 5: 48-50.
- Saleem TM, Chetty CM, Ramkanth S, Rajan VST, Kumar KM and Gauthaman K. Hepatoprotective herbs: A review. *Int J Res Pharm Sci*. 2010; 1: 1-5.
- Siddiqi HS, Mehmood MH, Rehman NU, Gilani AH. Studies on the antihypertensive and antidiyslipidemic activities of *Viola odorata* leaves extract. *Lipids Health Dis*. 2012; 11: 6.
- Singab ANB, Youssef DT, Noaman E, Kotb S. Hepatoprotective effect of flavonol glycosides rich fraction from Egyptian *Vicia calcarata* desf. Against CCl₄-induced liver damage in rats. *Arch Pharmacol Res*. 2005; 28: 791-98.
- Thakare SP, Jain HN, Patil SD, Upadhyay UM. Hepatoprotective effect of *Cocculus hirsutus* on bile duct ligation-induced liver fibrosis in albino Wistar rats. *Bangladesh J Pharmacol*. 2009; 4: 126-30.
- Vadivu R, Lakshmi KS. *In vitro* and *in vivo* anti-inflammatory activity of leaves of *Symplocos cochinchinensis* (Lour) Moore ssp *laurina*. *Bangladesh J Pharmacol*. 2008; 3: 121-24.

Author Info

M. Imran Qadir (Principal contact)
e-mail: mrinranqadir@hotmail.com