

BJP

Bangladesh Journal of Pharmacology

Research Article

Hepatoprotective and nephroprotective activity of hydroalcoholic extract of *Ipomoea staphylina* leaves

Hepatoprotective and nephroprotective activity of hydroalcoholic extract of *Ipomoea staphylina* leaves

Anupam Kanti Bag¹ and S. M. Firdous Mumtaz²

¹Department of Pharmacology, Ratnam Institute of Pharmacy, Pidathapolur Village, Muthukur SPSR Nellore, Andhra Pradesh 524 346, India; ²Department of Pharmacology, Calcutta Institute of Pharmaceutical Technology and AHS, Uluberia, Howrah 711 316, West Bengal, India.

Article Info

Received: 1 May 2013

Accepted: 13 May 2013

Available Online: 31 May 2013

DOI: 10.3329/bjp.v8i3.14845

Cite this article:

Bag AK, Mumtaz SMF. Hepatoprotective and nephroprotective activity of hydroalcoholic extract of *Ipomoea staphylina* leaves. Bangladesh J Pharmacol. 2013; 8: 263-68.

Abstract

The present study was undertaken to investigate the protective effect of hydroalcoholic extract of leaves of *Ipomoea staphylina* against carbon tetrachloride- and gentamicin-induced hepatotoxicity and nephrotoxicity in rats respectively. The extract (200 mg/kg, p.o) showed hepatoprotective activity against carbon tetrachloride-induced hepatotoxicity by significantly ($p < 0.001$) reducing the levels of AST, ALT, ALP, total bilirubin and significantly ($p < 0.001$) increasing the serum total protein. The extract also showed nephroprotective activity against gentamicin-induced nephrotoxicity by significantly ($p < 0.001$) reducing the levels of blood urea, blood urea nitrogen (BUN), serum creatinine and significantly ($p < 0.001$) increasing the serum total protein. The extract also improves the histology of the liver and kidney. The total phenolic content and the total flavonoid content of the extract were 94.6 ± 2.5 mg gallic acid equivalent/g and 44.7 ± 2.0 mg rutin equivalent/g respectively.

Introduction

The liver is an important organ responsible for the metabolism, bile secretion, elimination of many substances, blood detoxifications, synthesizes, and regulation of essential hormones. The reasons for the liver diseases in the developing countries are hepatitis viruses, environmental toxins and parasitic disease. Certain drugs such as antibiotics, chemotherapeutic agents, high doses of paracetamol, carbon tetrachloride (CCL₄), thioacetamide (TAA) causes hepatotoxicity (Saleem et al., 2010).

Kidney failure describes a medical condition in which the kidneys fail to adequately filter toxins and waste products from the blood. The two forms are acute and chronic; a number of other diseases or health problems may cause either form of renal failure to occur. Chronic kidney disease attacks the kidneys slowly and progressively over a period of time. It can take years for the damage to these organs to be noticeable because

there are no symptoms, which is why the disease is often called the "silent killer" (Levey et al., 2007).

Ipomoea staphylina is an extensive climber belonging to the family convolvulaceae. A literature review reveals antiulcer activity (Firdous and Nitesh, 2009) and anti-inflammatory activity (Firdous et al., 2012) of *I. staphylina*. Two compounds namely sitosteryl-3-O- β -D-glucoside and chiro deoxy inositol were isolated (Kota et al., 2013).

Materials and Methods

Plant material

Leaves of *I. staphylina* were collected from forest area of Karnataka near to Bangalore. The plant *I. staphylina* was taxonomically identified and authenticated by Dr. K. Karthigeyan at Central National Herbarium, Botanic Garden, Howrah, where the voucher specimen for the same is conserved under the reference number SMF-01.



Preparation of the extracts

The leaves of *I. staphylina* were cleaned and dried under shade at room temperature for several days and powdered. Same was defatted using petroleum ether (60-80 GR) for 72 hours and then ethyl alcohol and distilled water at the ratio of 7:3 was used for the extraction of the powdered leaves, which resulted with a yield of 10.2% w/w. The obtained dried extracts were stored in airtight container and placed in refrigerator.

Drugs and chemicals

Carbon tetrachloride was procured from E. Merck chemicals Pvt. Ltd, Mumbai, India, silymarin were obtained from Micro Labs, Bangalore, India and Gentamicin was procured from Piramal Health Care, Ahmedabad, India. ALT, AST, ALP, Total bilirubin, Total protein, Urea, Uric acid and Creatinine kits were obtained from Span Diagnostics, Surat, India. All other chemicals used in this study were obtained commercially and were of analytical grade.

Experimental animals

In-breed Wistar rats (150-200 g) of either sex were maintained under controlled conditions of temperature ($23 \pm 2^\circ\text{C}$) and humidity ($50 \pm 5\%$) and a 12 hours light/dark cycle, were used for the experiment. The animals were housed in sanitised polypropylene cages containing sterile paddy husk as bedding. They had free access to standard rat pellet diet and water *ad libitum*. The animals were given a week's time to get acclimatized with the laboratory conditions.

Acute toxicity studies

Rats were kept overnight fasting prior to drug administration. Animals received a single oral dose (2,000 mg/kg, b.w.) of hydroalcoholic extract of leaves of *I. staphylina*. After the administration of *I. staphylina* leaves extract, food was withheld for further 3-4 hours. Animals were observed individually at least once during the first 30 min after dosing, periodically during the first 24 hours (with special attention during the first 4 hours) and daily thereafter for a period of 14 days. Once daily cage side observations included changes in skin and fur, eyes and mucous membrane (nasal) and also respiratory rate, circulatory (heart rate and blood pressure), autonomic (salivation, lacrimation, perspiration, piloerection, urinary incontinence, and defecation) and central nervous system (ptosis, drowsiness, gait, tremors and convulsion) changes. Mortality, if any, was determined over a period of two weeks (OECD, 2002).

Selection of dose of the extract

LD₅₀ was done as per OECD guidelines for fixing the dose for biological evaluation. The LD₅₀ of *I. staphylina* leaf extract as per OECD guidelines falls under class four values with no signs of acute toxicity at 2,000 mg/kg. The biological evaluation was carried out at doses of

100 and 200 mg/kg body weight.

Estimation of total phenolic content

In brief, a 1 mL of sample (1 mg/mL) was mixed with 1 mL of Folin-Ciocalteu's phenol reagent. After 5 min, 10 mL of a 7% Na₂CO₃ solution was added to the mixture followed by the addition of 13 mL of deionized distilled water and mixed thoroughly. The mixture was kept in the dark for 90 min at 23°C, after which the absorbance was read at 750 nm. The TPC was determined from extrapolation of calibration curve which was made by preparing gallic acid solution. The estimation of the phenolic compounds was carried out in triplicate. The TPC was expressed as milligrams of gallic acid equivalents (GAE) per g of dried sample (Kim et al., 2003).

Estimation of total flavonoid content

In a 10 mL test tube, 0.3 mL of extract, 3.4 mL of 30% methanol, 0.15 mL of NaNO₂ (0.5 M) and 0.15 mL of AlCl₃.6H₂O (0.3 M) were mixed. After 5 min, 1 mL of NaOH (1 M) was added. The solution was mixed well and the absorbance was measured against the reagent blank at 506 nm. The standard curve for total flavonoids was made using rutin standard solution (0 to 100 mg/L) under the same procedure as earlier described. The total flavonoids were expressed as milligrams of rutin equivalents per g of dried fraction (Park et al., 2008).

Carbon tetrachloride-induced hepatotoxicity in rats (Jain et al., 2009; Ahsan et al., 2009)

Thirty Wistar albino rats of either sex were assigned to five groups (n=6): Group I: Animals were administered a single dose of water (1 mL/kg, p.o.) daily for 5 days and received liquid paraffin (1 mL/kg, s.c.) on day 2 and 3. Group II: Animals were administered distilled water (1 mL/kg, p.o.) once daily for 5 days and received CCl₄: liquid paraffin (1:1, 2 mL/kg, s.c.) on day 1, 2 and 3. Group III: Animals were received silymarin (50 mg/kg, p.o.) once daily for 5 days and received CCl₄: liquid paraffin (1:1, 2 mL/kg, s.c.) on day 2 and 3. Group IV: Animals were received extract of *I. staphylina* (200 mg/kg, p.o.). Group V: Animals were received extract of *I. staphylina* (100 mg/kg, p.o.).

Test group animals (Groups IV and V) were administered orally hydroalcoholic extracts once daily for 5 days and received CCl₄: liquid paraffin (1:1, 2 mL/kg, s.c.) on day 2 and 3. Animals were sacrificed 24 hours after the last treatment. Blood was collected by retro orbital sinus puncture and serum was separated by centrifugation. Rats were sacrificed; livers were excised, rinsed clean in saline and preserved in 10% formalin for histopathological study.

Gentamicin-induced nephrotoxicity in rats (Harlalka et al., 2007)

Twenty-four Wistar albino rats of either sex were assigned to four groups (n = 6): Group I: Rats in this

group were injected with normal saline, intra-peritoneally and served as control; Group II: Rats in this group were injected with gentamicin (100 mg/kg, i.p) for seven consecutive days; Group III: Rats in this group were injected with gentamicin (100 mg/kg, i.p) and administered extract of *I. staphylina* (200 mg/kg, p.o) for seven consecutive days; Group IV: Rats in this group were injected with gentamicin (100 mg/kg, i.p) and administered extract of *I. staphylina* (100 mg/kg, p.o) for seven consecutive days.

After the last dosing of seventh day after 24 hours the blood sample were collected by puncturing retro-orbital plexus and serum was separated by centrifugation. Rats were sacrificed; kidneys were excised, rinsed clean in saline and preserved in 10% formalin for histopathological study.

Histopathological studies

Portions of the liver and kidney from all the experimental groups were fixed in 10% formalin, dehydrated in alcohol and then embedded in paraffin. Microtome sections (5 μ m thick) were prepared from each liver sample and stained with hematoxylin-eosin (H & E) dye. The sections were examined for the pathological findings.

Statistical analysis

Results were expressed Mean \pm SEM from six animals in each group. Comparison between the groups were made by using one way analysis of variance (ANOVA), followed by Tukey-Kramer Multiple Comparisons Test with the help of INSTAT software. $p < 0.05$ was considered as statistically significant.

Results

The hydroalcoholic extract of leaves *I. staphylina* was

found to contain 94.6 ± 2.5 mg gallic acid equivalent/g of phenolics while the total flavonoid contents were 44.7 ± 2.0 mg rutin equivalent/g.

In CCl_4 induced hepatotoxicity the activities of serum hepatic marker enzymes namely aspartate aminotransferase (AST), alanine aminotransferase (ALT) and alkaline phosphatase (ALP) and total bilirubin level showed a significant ($p < 0.001$) increase in CCl_4 treated animals as compared to control group and the total serum protein concentration was significantly ($p < 0.001$) lower in CCl_4 treated group (Table I). Administering *I. staphylina* (200 mg/kg, p.o) significantly reduced the levels of AST, ALT, ALP and total bilirubin level in CCl_4 treated rats as compared to the group treated with CCl_4 alone and the total serum protein concentration was significantly increased (Table I).

In gentamicin induced nephrotoxicity, gentamicin treated group showed a significant ($p < 0.001$) increase in blood urea, blood urea nitrogen and serum creatinine as compared to control group and the total serum protein concentration was significantly ($p < 0.001$) lower in gentamicin treated group. Administering hydro-alcoholic extract of *I. staphylina* (200 mg/kg, p.o) significantly ($p < 0.001$) reduced the levels of blood urea, blood urea nitrogen and serum creatinine in gentamicin treated rats as compared to the animals treated with gentamicin treated group alone and the total serum protein concentration was significantly ($p < 0.001$) increased (Table II).

The histological examination (Figure 1) shows the effect of silymarin, *I. staphylina* leaves extract on CCl_4 induced hepatotoxicity in rats. Control group (A) animals showed a normal hepatic architecture. In CCl_4 treated group (B), severe hepatotoxicity was evidenced by kupffer cell hyperplasia, inflammatory cells, apoptosis, microvascular fatty changes and centrilobular necrosis.

Table I

Effect of ethanol extract of leaves of *Ipomoea staphylina* on serum level of aspartate aminotransferase (AST), alanine aminotransferase (ALT), alkaline phosphatase (ALP), total protein (TP) and total bilirubin (TB) in experimental groups

Groups	Treatment	AST IU/L	ALT IU/L	ALP IU/L	Total protein gm/dL	Total bilirubin gm/dL
I	Normal Control	58.3 ± 2.7	88.6 ± 2.5	127.6 ± 3.5	7.2 ± 0.1	1.0 ± 0.0
II	CCl_4 Treated	260.6 ± 4.9^a	426.8 ± 3.2^a	274.7 ± 5.0^a	3.6 ± 0.2^a	5.5 ± 0.1^a
III	Silymarin (100 mg/kg)	93.0 ± 4.0^b	195.0 ± 6.6^b	135.8 ± 4.2^b	6.4 ± 0.2^b	2.2 ± 0.2^b
IV	<i>Ipomoea staphylina</i> (200 mg/kg)	99.5 ± 4.0^b	226.2 ± 6.0^b	153.2 ± 5.8^b	5.5 ± 0.2^b	2.5 ± 0.1^b
V	<i>Ipomoea staphylina</i> (100 mg/kg)	142.2 ± 4.5^b	299.3 ± 3.7^b	215.9 ± 7.0^b	4.5 ± 0.3	3.4 ± 0.2^b

Values are expressed as mean \pm SEM, n = 6; ^a $p < 0.001$ considered statistically significant as compared to normal control group; ^b $p < 0.001$ considered statistically significant as compared to CCl_4 treated group

Table II					
Effect of hydroalcoholic extract of leaves of <i>Ipomoea staphylina</i> on blood urea, blood urea nitrogen and serum creatinine in experimental groups					
Groups	Treatment design	Blood urea (mg/100 mL)	Blood urea nitrogen (mg/100 mL)	Serum creatinine (mg/100 mL)	Total protein (mg/dL)
I	Normal Control	18.0 ± 1.3	8.4 ± 0.6	0.5 ± 0.0	7.3 ± 0.4
II	Gentamicin (100 mg/kg)	70.2 ± 2.6 ^a	32.8 ± 1.2 ^a	2.2 ± 0.1 ^a	2.7 ± 0.2 ^a
III	<i>Ipomoea staphylina</i> (200 mg/kg)	46.5 ± 1.7 ^b	21.7 ± 0.8 ^b	0.8 ± 0.0 ^b	5.4 ± 0.3 ^b
IV	<i>Ipomoea staphylina</i> (100 mg/kg)	61.4 ± 2.0 ^c	28.7 ± 0.9 ^c	1.5 ± 0.1 ^b	3.9 ± 0.3

Values are expressed as mean ± SEM, n = 6; ^ap<0.001 considered statistically significant as compared to normal control group; ^bp<0.001 and ^cp<0.05 considered statistically significant as compared to gentamicin treated group

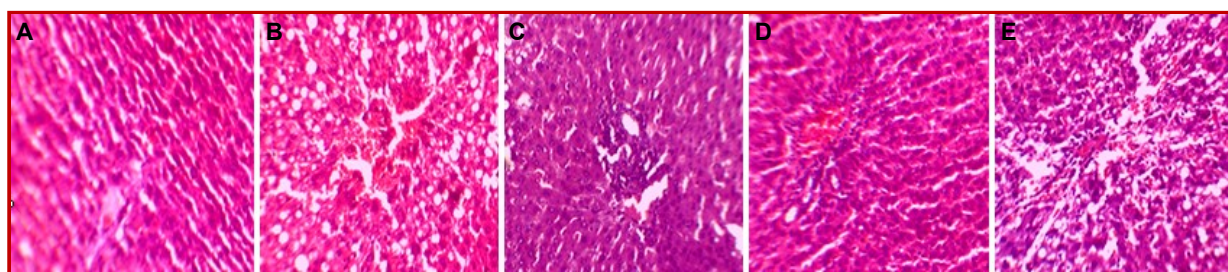


Figure 1: Effect of hydroalcoholic extract of leaves of *Ipomoea staphylina* on CCL₄-induced hepatotoxicity in rats. A: Normal control; B: Treated with carbon tetrachloride (2 mL/kg, s.c); C: Treated with silymarin (50 mg/kg); D: Treated with *Ipomoea staphylina* (200 mg/kg); E: Treated with *Ipomoea staphylina* (100 mg/kg)

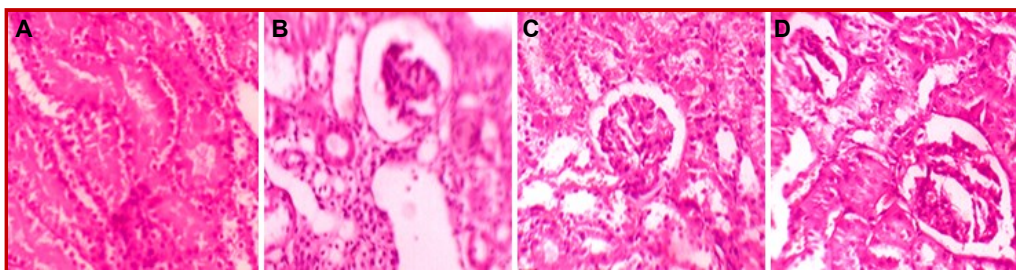


Figure 2: Effect of hydroalcoholic extract of leaves of *Ipomoea staphylina* on gentamicin-induced nephrotoxicity in rats. A: Normal control; B: Treated with gentamicin (100 mL/kg, i.p); C: Treated with *Ipomoea staphylina* (200 mg/kg); D: Treated with *Ipomoea staphylina* (100 mg/kg)

Treatment with silymarin (C) showed normal architecture with less fatty changes. Hydroalcoholic extract of *I. staphylina* leaves (D, E) at the dose of 200 and 100 mg/kg, p.o. reduced such changes in kidney histology.

In gentamicin induce nephrotoxicity model normal control rats (Figure 2A) showed normal glomerular and tubular histology whereas gentamycin treated group was found to cause distorted tubular shape, cellular infiltration of the tubules (tubulitis), glomerular and blood vessel congestion, and also result in the presence of inflammatory cells in kidney sections (Figure 2B). The concurrent treatment with the extract of leaves of *I. staphylina* (200 mg/kg, p.o.) reduced such changes in kidney histology (Figure 2C).

Discussions

In hepatoprotective experiment carbon tetrachloride was used to induce hepatotoxicity by metabolic activation, therefore, it selectively causes toxicity in liver cells maintaining normal metabolic function. Carbon tetrachloride is accumulated in hepatic parenchyma cells and metabolically activated by the cytochrome P-450 dependent mixed oxidase in the endoplasmic reticulum to form trichloromethyl free radical (*CCl₃) which combined with cellular lipids and proteins in the presence of oxygen to induce lipid peroxidation (Krishna et al., 2009). These resulted in changes of structures of the endoplasmic reticulum and other membrane, loss of metabolic enzyme activation,

elevated level of serum marker enzymes like AST, ALT, ALP, reduction of protein synthesis, increased lipid peroxidation and destruction of Ca^{2+} homeostasis (Kaplowitz et al., 1986).

The impairment in the transport function of the hepatocytes causes the leakage of enzymes from cells due to altered permeability of membrane, which results in decreased levels of AST, ALT and ALP in the hepatic cells and a raised level in serum. For such assessment of liver damage by CCl_4 hepatotoxin, the enzyme levels such as AST and ALT is largely considered (Al-Howiriny et al., 2004). Serum ALP and bilirubin levels on the other hand, are related to the function of hepatic cell. Increase in serum level of ALP is due to increased synthesis, in presence of increasing biliary pressure. Bilirubin is one of the most useful clinical clues for the severity of necrosis and its accumulation is a measure of binding, conjugation and excretory capacity of hepatocyte (Manokaran et al., 2008). A reduction in total serum protein observed in the CCl_4 treated group may be associated with the decrease in the number of hepatocytes which in turn may result into decreased hepatic capacity to synthesize protein (Mulla et al., 2009). In CCl_4 -induced hepatotoxicity in rats, our results suggest that the treatment with *I. staphylina* extract and its different fractions significantly reduced the enhanced level of serum ALT, AST which seem to offer the protection and maintain the functional integrity of hepatic cells. Effective control of bilirubin level and alkaline phosphatase activity by different doses of the extract and its fractions points towards an early improvement in the secretory mechanism of the hepatic cell. The significant raise in protein levels suggests the stabilization of endoplasmic reticulum leading to protein synthesis (Firdous et al., 2008). These results indicate that the *I. staphylina* hydroalcoholic extract preserved structural integrity of the hepatocellular membrane and showed dose dependant protective effect.

Nephrotoxicity induced by gentamicin is characterized by a decrease in the glomerular filtration rate and tubular injury due to the formation of reactive oxygen species (ROS), which may be directly involved in membrane lipid peroxidation, mesangial cells contraction, which alters the filtration surface area and modify the ultrafiltration coefficient and decrease the glomerular filtration rate (Poormoosavi et al., 2010). Management of such renal hemodynamic abnormality and reduction of the same are important to prevent the deterioration of normal functions of kidney. Formation of non-protein nitrogenous compound such as urea and creatinine takes place due to degradation of these protein and nucleic acids (Punitha et al., 2005).

Changes in the levels of serum urea, creatinine and uric acid concentrations strongly suggested impairment of

kidney function in diabetes. Administration of hydroalcoholic extract of leaves of *I. staphylina* decreased the levels of serum urea, creatinine, uric acid and protein level in treated groups significantly.

This hepatoprotective and nephroprotective activity of the *I. staphylina* extracts may be due to antioxidant activity which may be due to the presence of flavanoids and phenolic compounds.

Conclusion

This study demonstrates the hepatoprotective and nephroprotective activity of hydroalcoholic extract of *I. staphylina* leaves.

Financial Support

Self-funded

Ethical Issue

All the experimental procedures were performed according to the committee for the purpose of control and supervision of experiments on animals (CPCSEA), ministry of social justice and empowerment Government of India, norms and approved by the Institutional Animal Ethics Committee (IAEC).

Conflict of Interest

Authors declare no conflict of interest

References

- Ahsan MR, Islam KM, Bulbul IJ, Musaddik MA, Haque E. Hepatoprotective activity of methanol extract of some medicinal plants against carbon tetrachloride-induced hepatotoxicity in rats. *Eur J Sci Res.* 2009; 37: 302-10.
- Al-Howiriny TA, Al-Sohaibani MO, Al-Said MS, Al-Yahya MA, El-Tahir KH, Rafatullah S. Hepatoprotective properties of *Commiphora opobalsamum* ("Balessan"), a traditional medicinal plant of Saudi Arabia. *Drugs Exp Clin Res.* 2004; 30: 213-20.
- Firdous M, Nitesh SC. Evaluation of antiulcer activity of *Ipomoea staphylina*. *Pharmacol Online.* 2009; 3: 195-99.
- Firdous SM, Raju K. *In vivo* and *in vitro* antiinflammatory activity of leaves of *Ipomoea staphylina*. *Int J Pharm Pharm Sci.* 2012; 4: 339-43.
- Firdous SM, Raju K, Pallab H. Evaluation of hepatoprotective activity of saponin of *Momordica dioica* roxb. Against CCl_4 induced hepatic injury in rats. *Pharmacolonline.* 2008; 3: 487-94.
- Harlalka GV, Patil CR, Patil MR. Protective effect of *Kalanchoe*

- pinnata* pers. (crassulaceae) on gentamicin-induced nephrotoxicity in rats. Indian J Pharmacol. 2007; 39: 201-05.
- Jain S, Dixit VK, Malviya N, Ambawatia V. Anti-oxidant and hepatoprotective activity of ethanolic and aqueous extracts of *Amorphophallus campanulatus* roxb. tubers. Acta Polonica Pharm Drug Res. 2009; 66: 423-28.
- Kaplowitz N, Aw TY, Simon FR, Stolz A. Drug induced hepatotoxicity. Ann Intern Med. 1986; 104: 826-39.
- Kim DO, Jeong SW, Lee CY. Anti-oxidant capacity of phenolic phytochemicals from various cultivars of plums. Food Chem. 2003; 81: 321-26.
- Krishna KL, Mruthunjaya K, Patel JA. Anti-oxidant and hepatoprotective activity of leaf extract of *Justica gendrerussa*. Int J Biol Chem. 2009; 3: 99-110.
- Levey AS, Atkins R, Coresh J, Cohen EP, Collins AJ, Eckardt KU, Nahas ME, Jaber BL, Jadoul M, Levin A, Powe N R, Rossert J, Wheeler DC, Lameire N, Eknoyan G. Chronic kidney disease as a global public health problem: Approaches and initiatives - a position statement from Kidney Disease Improving Global Outcomes. Kidney Int. 2007; 72: 247-59.
- Manokaran S, Jaswanth A, Sengottuvelu S, Nandhakumar J, Duraisamy R, Karthikeyan D, Mallegaswari R. Hepatoprotective activity of *Aerva lanata* Linn. against Paracetamol induced hepatotoxicity in rats. Res J Pharm Technol. 2008; 1: 398-400.
- Mulla WA, Salunkhe VR, Bhise SB. Hepatoprotective activity of hydroalcoholic extract of leaves of *Alocasia indica* (Linn.). Indian J Exp Biol. 2009; 47: 816-21.
- OECD, Acute oral toxicity. Acute oral toxic class method guideline 423 adopted 23.03.1996. In: Eleventh Addendum to the, OECD, guidelines for the testing of chemicals organisation for economics co-operation, development, Paris, June, 2002, p 11.
- Park YS, Jung ST, Kang SG, Heo BG Arancibia-Avila P, Toledo F, Drzewiecki J, Namiesnik J, Gorinstein S. Anti-oxidants and proteins in ethylene-treated kiwifruits. Food Chem. 2008; 107: 640-48.
- Poormoosavi SM, Behmanesh MA, Najafzadeh H. Effect of cimetidine on gentamicin-losartan induced-nephrotoxicity in rats. Afr J Pharm Pharmacol. 2010; 4: 341-45.
- Punitha ISR, Shirwaikar A, Shirwaikar A. Anti-diabetic activity of benzyltetraisoquinoline alkaloid berberine in streptozotocin nicotinamide induced type 2 diabetic rats. Diabetologia Croatica. 2005; 34: 117-28.
- Saleem TSM, Chetty CM, Ramkanth S, Rajan VST, Kumar KM, Gauthaman K. Hepatoprotective herbs: A review. Int J Res Pharm Sci. 2010; 1: 1-5.
- Reddy DP, Kota R, Renuka S, Anarthe SJ, Raghavendra NM. Isolation, characterization of phytoconstituents and pharmacological screening of *Ipomoea staphylinia*. Asian J Pharm Clin Res. 2013; 6: 30-33.

Author Info

S. M. Firdous Mumtaz (Principal contact)
e-mail: firdous_cology@rediffmail.com