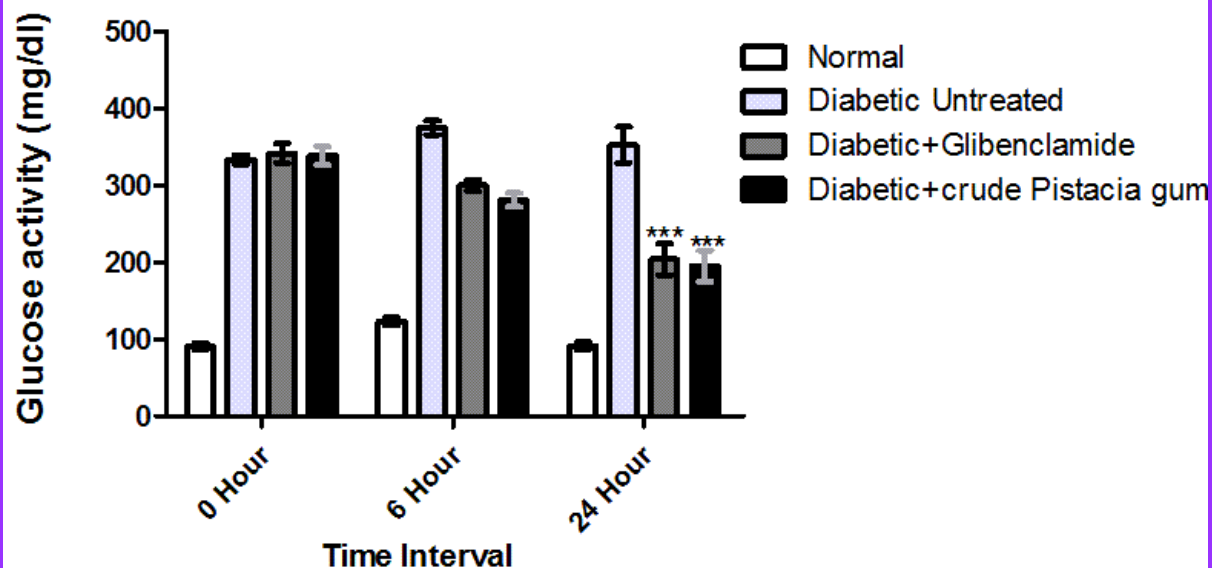

**BJP**

**Bangladesh Journal of Pharmacology**

**Research Article**

**Anti-diabetic activity of crude  
*Pistacia lentiscus* in alloxan-induced  
diabetes in rats**

## Anti-diabetic activity of crude *Pistacia lentiscus* in alloxan-induced diabetes in rats

Muhammad Saad Ur Rehman, Sairah Hafeez Kamran, Mobasher Ahmad and Usman Akhtar

University College of Pharmacy, University of the Punjab, Lahore, Pakistan.

### Article Info

Received: 4 May 2015

Accepted: 17 May 2015

Available Online: 1 July 2015

DOI: 10.3329/bjp.v10i3.23225

Cite this article:

Rehman MSU, Kamran SH, Ahmad M, Akhtar U. Antidiabetic activity of crude *Pistacia lentiscus* in alloxan-induced diabetes in rats. Bangladesh J Pharmacol. 2015; 10: 543-47.

### Abstract

The purpose of this study was to investigate the anti-diabetic effect of crude *Pistacia lentiscus* gum (mastic gum) in alloxan-treated diabetic rat model. The crude *P. lentiscus* (100 mg/kg) showed significant ( $p < 0.001$ ) reduction in blood glucose as compared to control. Liver function test also showed significant changes ( $p < 0.001$ ) as compared to alloxan-treated group. The results of this study showed that crude *P. lentiscus* gum have considerable efficacy in curing diabetes and have hepatoprotective effect.

### Introduction

Diabetes mellitus is a great healthcare problem in Asia as compared to rest of the world. It is expected that by 2030 six of the 10 countries expected to have the highest number of diabetic patients will be in Asia (Ku et al., 2013). Worldwide, herbal medicines are traditionally used for the treatment of diabetes mellitus. However, the area where herbal treatment is practiced, the scientific data regarding the efficacy of these drugs is not available (Baldé et al., 2006).

*Pistacia lentiscus* belonging to the family Anacardiaceae, is spread in the regions of France, Spain, Portugal, Greece, Turkey, Africa. The resin of *P. lentiscus* also referred to as "Arabic gum" or "mastic". The leaf and other plant parts may contain compounds absent in the resin. Mastic has antibacterial and antifungal properties. It also acts as an antioxidant (Hosseinzadeh et al., 2012; Koutsoudaki et al., 2005), used in the treatment of peptic ulcer (Huwez et al., 1998), mild effects against helicobacter pylori (Paraschos et al., 2007), chewing mastic can prevent tooth and gingivitis due to its antibacterial properties (Aksoy et al., 2006; Takahashi et al., 2003), in the preparation of bandages and skin

ointments (Triantafyllou et al., 2007). Various activities of the plant have already been reported in ancient literature but its therapeutic potential is still lacking.

The main objective of this study was to investigate the hypoglycemic effect and liver function tests of *P. lentiscus* in alloxan-induced diabetic rats. The possible effect of the plant in alloxan-induced diabetic rats was compared with glibenclamide, anti-diabetic drug.

### Materials and Methods

#### Plant materials

Mastic gum, the gum of plant *P. lentiscus* was obtained from Papar Mandi in Lahore, Punjab, Pakistan from a well-known dealer and was standardized according to the B.P. The gum was then ground into fine powder form in pestle and mortar. To achieve content uniformity the ground powder was passed through sieve of 42 mesh size and stored in air tight glass jar at room temperature, protected from exposure to light and moisture throughout the research work.



### Preparation of crude mastic gum suspension (*P. lentiscus*)

Fresh suspension was prepared daily and Tween 80 was used as a suspending agent. The measured amount of mastic gum powder was triturated with water in pestle and mortar, then a few drops of tween 80 were added until uniform paste like consistency achieved. Then water was added with continuous trituration until final suspension formed. The suspension was given to the animals orally by metal dozer.

### Animals

Male albino rats weighing 180-210 g were used. They were acclimatized to animal house conditions. The rats were fed standard rat chow and had free access to water and food until treatment.

### Experimental design

Diabetes was induced by intraperitoneal administration of alloxan monohydrate (150 mg/kg) (Rao and Rao, 2001). After 3 days, animals with 200-400 mg/dL blood glucose or higher were selected and used in experiment. For acute study, rats were divided into four groups of five rats each; group I (normal rats); group II (diabetic untreated rats); group III (diabetic treated with standard drug glibenclamide); group IV (diabetic treated with crude *Pistacia* gum 100 mg/kg). Blood glucose was estimated at 6 hours and 24 hours after the dose. For chronic study, rats were divided into four groups of five rats each; Group I (normal rats); Group II (diabetic untreated rats); Group III (diabetic treated with glibenclamide); Group IV (diabetic treated with crude *Pistacia* gum 100 mg/kg). Blood glucose and serum ALT, AST were estimated at regular intervals, ie., 7th, 14th and 21st day during chronic treatment with extract and glibenclamide.

### Blood biochemistry

Blood samples were taken from all experimental groups. Serum was isolated from blood of all animal groups at different hours in acute study and at different days in chronic study. The amount of serum Blood glucose (GOD/POD method) (Sushruta et al., 2007) AST, ALT was estimated using commercial kits according to the manufacturer's protocol.

### Statistical analysis

Different treatment group's vs control groups was performed by one-way ANOVA with Bonferroni post-hoc test using Graphpad Prism. P-value of less than 0.05 was considered statistically significant.

### Phytochemical test of *P. lentiscus*

**Test for alkaloids:** Dragondroff's reagent was used for the detection of alkaloids in the methanolic extract of the plant. The methanolic extract of the plant was spotted on the TLC plate. The TLC plate was sprayed

with Dragondroff's reagent. Bright yellow spots appeared on the TLC plate which indicated the presence of alkaloid in the methanolic extract.

**Test for flavonoids:** The methanolic extract of the plant was spotted on the TLC plate for the detection of flavonoids. The TLC plate was then sprayed with aluminum chloride. Bright yellow fluorescence appeared on long wavelength which indicated the presence of flavonoids in the methanolic extract.

For the confirmation of presence of flavonoids in the *P. lentiscus*, the methanolic extract of the plant was spotted on the TLC plate. The TLC plate was then sprayed with antimony chloride. The plate was then observed in long UV wavelength. Bright fluorescence appeared which confirmed the presence of flavonoids.

**Test for steroids, phenols and sugars:** Methanolic extract of *P. lentiscus* was spotted on TLC plate, the plate was then sprayed with anisaldehyde. Red colored spots appeared which indicated the presence of steroids, sugars and phenols in the methanolic extract of the plant.

Methanolic extract of *P. lentiscus* was spotted on the TLC plate, concentrated sulphuric acid was applied to the plate. Brown color appeared confirming the presence of sugars in the methanolic extract.

**Test for lipids:** For the detection of lipids in the methanolic extract of *P. lentiscus*, the extract was spotted on TLC plate, the plate was then sprayed with 2, 7-dichlorofluorescein. Fluorescence appeared on the plate indicating the presence of lipids.

**Test for terpenes:** TLC plate was spotted with methanolic extract of the plant. Ceric sulphate was then sprayed on the TLC plate. The spot turned dark brown which indicated the presence of terpenes or terpenoids in the plant.

**Test for saponins:** Methanolic extract of plant was mixed with equal quantity of water in a test tube. Test tube was shaken vigorously. No foam appeared on vigorous shaking. This indicated the absence of saponins in the plant extract.

---

## Results

The effect of treatment with glibenclamide and crude *P. lentiscus* in diabetic rats were compared and shown in Figure 1 and 2. Blood glucose levels in diabetic rats were significantly higher than treated group at 0,6,24 hour interval ( $p < 0.001$ ). After 6 hour, there was decreased in blood glucose ( $280.8 \pm 9.0$ ) but after 24 hour crude *Pistacia* gum showed significant decrease ( $195.2 \pm 20.4$ ) as compared to diabetic untreated ( $352.4 \pm 23.6$ ) rats as shown in Figure 1.

In chronic administration of crude *P. lentiscus* showed highly significant decreased in blood glucose level

( $p < 0.001$ ) as measured at 7<sup>th</sup> day ( $193.6 \pm 29.7$ ), 14<sup>th</sup> day ( $169.6 \pm 17.0$ ), 21<sup>st</sup> day ( $145.8 \pm 7.5$ ) as compared to diabetic untreated at 7<sup>th</sup> day ( $349.4 \pm 23.6$ ), 14<sup>th</sup> day ( $330.8 \pm 11.0$ ) and 21<sup>st</sup> day ( $337.0 \pm 16.5$ ) while there was no significant difference ( $p > 0.05$ ) when compared with glibenclamide.

To further evaluate the role of crude *P. lentiscus* on liver after continuous administration of 21 days, serum level

of AST and ALT were analyzed in all groups as shown in Figure 3. Serum level of ALT was significantly lowered in crude *P. lentiscus* treated group at 21<sup>st</sup> day ( $12.8 \pm 0.8$ ) as compared to diabetic untreated ( $34.0 \pm 1.8$ ) and glibenclamide-treated groups ( $22.1 \pm 1.9$ ). In addition, serum ALT level was also significantly lowered in crude *P. lentiscus*-treated group at 21<sup>st</sup> day ( $6.6 \pm 0.7$ ) as compared to diabetic untreated ( $41.0 \pm 2.2$ )

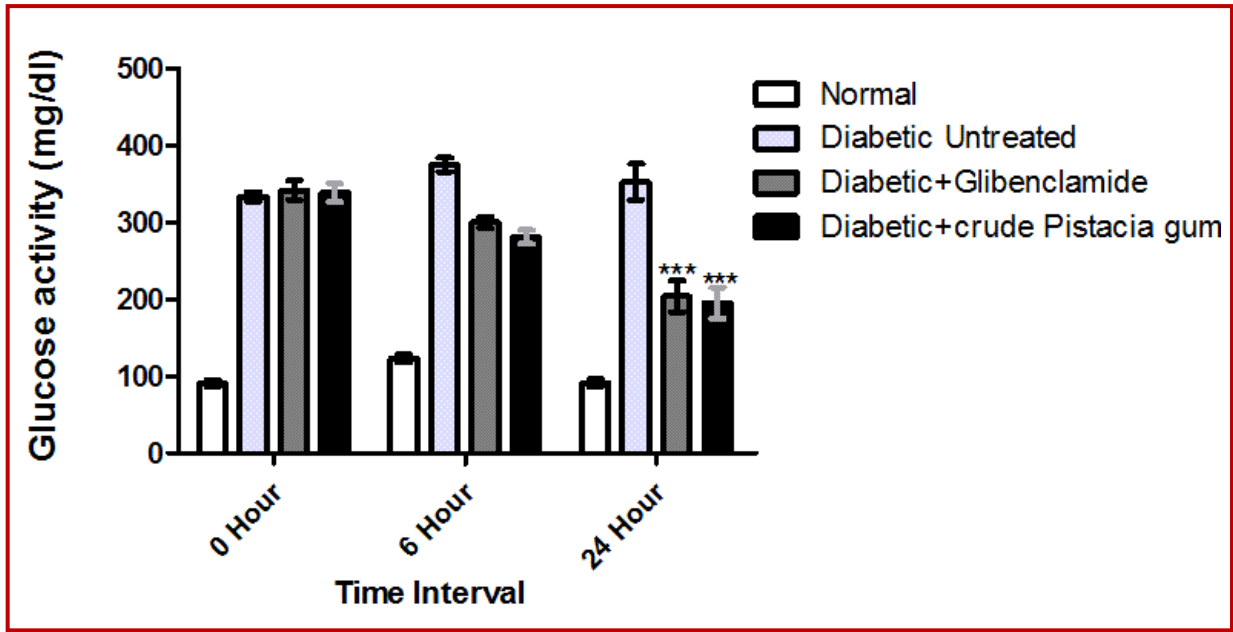


Figure 1: Acute glucose activity in serum of all animal groups; \*\*\* $p < 0.001$  for diabetic plus crude *Pistacia gum* 24 hours vs diabetic untreated 24 hours; \*\*\* $p < 0.001$  for diabetic plus glibenclamide 24 hours vs diabetic untreated 24 hours

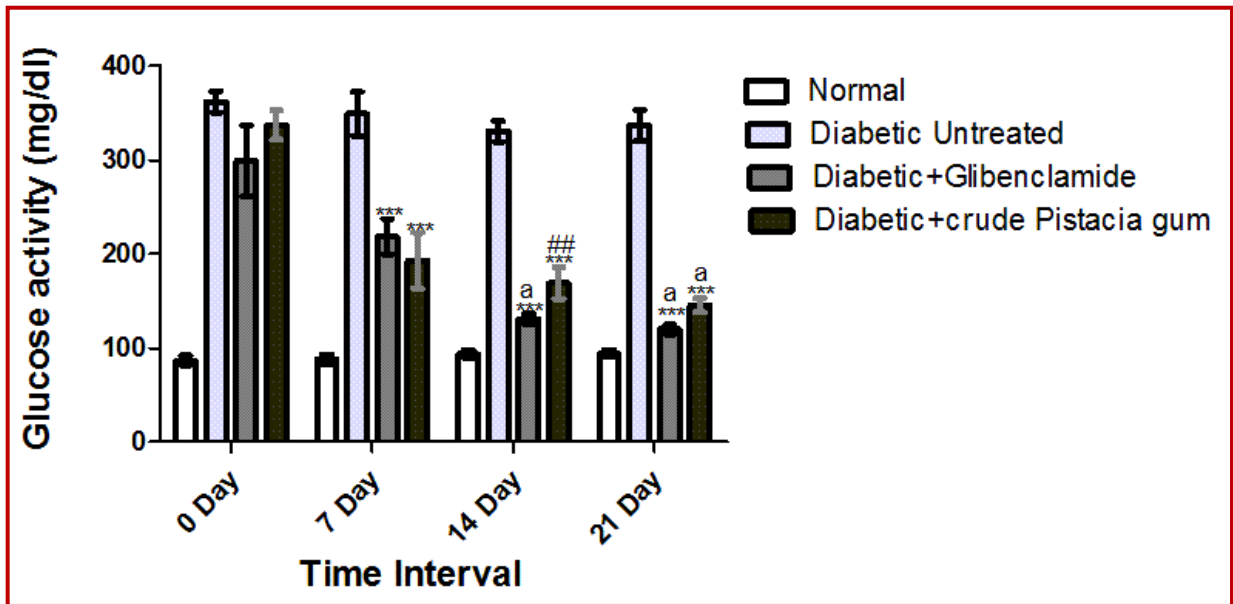


Figure 2: Chronic glucose activity in serum of all animals groups; \*\*\* $p < 0.001$  for diabetic plus crude *Pistacia gum*; diabetic plus glibenclamide 7 days vs diabetic untreated 7 days; \*\*\* $p < 0.001$  for diabetic plus crude *Pistacia gum*; diabetic plus glibenclamide 14 days vs diabetic untreated 14 days;  $a$   $p > 0.05$  diabetic plus glibenclamide 14 days vs normal 14 days; ##  $p < 0.01$  for diabetic plus crude *Pistacia gum* 14 days vs normal 14 days; \*\*\* $p < 0.001$  for diabetic plus crude *Pistacia gum*; diabetic plus glibenclamide 21 days vs diabetic untreated 21 days;  $a$   $p > 0.05$  diabetic plus glibenclamide; diabetic plus crude *Pistacia gum* 21 days vs normal 21 days

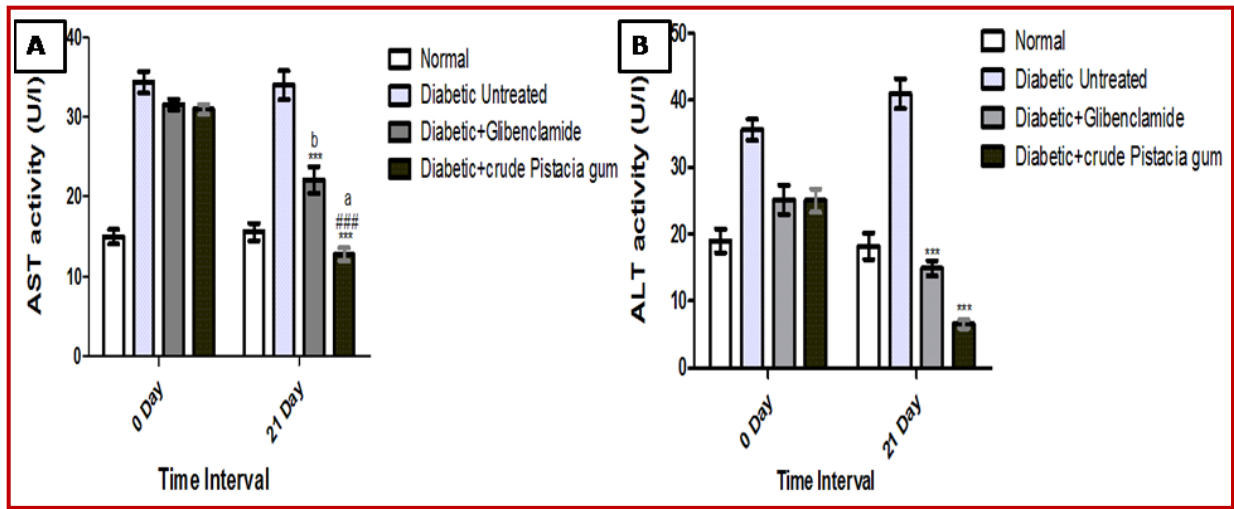


Figure 3: Liver function tests. Treatment groups. A) AST in serum of all animals groups; \*\*\* $p < 0.001$  for diabetic plus glibenclamide; diabetic plus crude *Pistacia* gum 21 days vs diabetic untreated 21 days; ### $p < 0.001$  for diabetic plus glibenclamide vs diabetic + crude *Pistacia* gum 21 days;  $b p < 0.01$  for diabetic plus glibenclamide 21 days vs normal 21 days;  $a p > 0.05$  for diabetic plus crude *Pistacia* gum 21 days vs normal 21 days; B) ALT in serum of all animals groups; \*\*\* $p < 0.001$  for diabetic + glibenclamide; diabetic plus crude *Pistacia* gum 21 days vs diabetic untreated 21 days

and glibenclamide-treated groups ( $14.9 \pm 1.1$ ).

## Discussion

In current study, we have investigated the anti-diabetic potential in alloxan-induced diabetes. Alloxan induced diabetes produces selective cytotoxicity in  $\beta$ -cells of pancreas through the generation of free radicals resulting in reduced synthesis and release of insulin (Sakurai et al., 2001). In acute study, mastic gum showed significant decrease in blood glucose that was comparable to glibenclamide by rapid normalization of blood glucose levels while high glucose level was observed in alloxan-treated groups throughout the total time period of study. It is possible that mastic gum and glibenclamide bring about release of insulin from the  $\beta$ -cells of pancreas, resulting in normalization of blood glucose. Then we study the chronic administration of mastic gum for 21 days for its anti diabetic effect. It showed highly significant decrease in blood glucose as shown in Figure 2 at different day's interval.

The increase in the plasma concentration of AST, ALT indicated that in diabetic patient there is induced hepatic dysfunction. Liver is necrotized in diabetic patients (Larcan et al., 1979). The concentration of these enzymes increased in plasma mainly due to the leakage from the cytosol of liver into blood stream (Navarro et al., 1993) which is a good indicator of hepatotoxic effect of alloxan. In current study, treatment of diabetic rats with mastic gum caused reduction in the concentration of these enzymes in plasma at different days interval compared to the mean values of diabetic untreated rats.

The reduction in AST, ALT is due to outflow of

enzymes into the blood as a consequence of alloxan toxicity which causes liver damage. However, crude *Pistacia* gum treatment groups for 21 days could restore the activities of the above enzymes to their normal levels. This Study shows that crude *P. lentiscus* acts as anti diabetic and hepatoprotective effect.

## Conclusion

The crude *P. lentiscus* has antihyperglycemic activity as it lowers serum glucose level in diabetic rats and significantly increases glucose tolerance. It also improves the micro environment of liver.

## Financial Support

Self-funded

## Ethical Issue

The research conforms to the Guide for the care and Use of Laboratory Animals by the US National institutes of Health (NIH publication No. 85-23, revised 1985). All animals were treated according to the procedures approved by the Institutional Ethical Committee at the University College of Pharmacy, University of the Punjab, Lahore, Pakistan.

## Conflict of Interest

Authors declare no conflicts of interest

## Acknowledgments

We thank our colleagues for the review of this manuscript. We

thank faculty of University College of Pharmacy for their support during research.

---

## References

- Aksoy A, Duran N, Koksali F. *In vitro* and *in vivo* antimicrobial effects of mastic chewing gum against *Streptococcus mutans* and mutans streptococci. *Arch Oral Biol.* 2006; 51: 476-81.
- Baldé NM, Youla A, Balde MD, Kake A, Diallo MM, Baldé MA, Maugendre D. Herbal medicine and treatment of diabetes in Africa: An example from Guinea. *Diabetes Metab J.* 2006; 32: 171-75.
- Hosseinzadeh H, Sajadi Tabassi SA, Milani Moghadam N, Rashedinia M, Mehri S. Antioxidant activity of *Pistacia vera* fruits, leaves and gum extracts. *Iran J Pharm Res.* 2012; 11: 879-87.
- Huwez FU, Thirlwell D, Cockayne A, Ala'Aldeen DAA. Mastic gum kills *Helicobacter pylori*. *New Engl J Med.* 1998; 339: 1946-46.
- Koutsoudaki C, Krsek M, Rodger A. Chemical composition and antibacterial activity of the essential oil and the gum of *Pistacia lentiscus* Var. chia. *J Agric Food Chem.* 2005; 53: 7681-85.
- Ku G, Kegels G. The performance of the Finnish diabetes risk score: A modified Finnish diabetes risk score and a simplified Finnish diabetes risk score in community-based cross-sectional screening of undiagnosed type 2 diabetes in the Philippines. *Prim Care Diabetes.* 2013; 7: 249-59.
- Larcan A, Lambert H, Laprevote-Heully MC, Delorme N. [Light and electron microscopic study of hepatic lesions in the course of hyperlactatemia in diabetic patients (author's transl)]. *Diabete Metabolisme.* 1979; 5: 103-12.
- Concepción Navarro M, Pilar Montilla M, Martín A, Jiménez J, Pilar Utrilla M. Free radical scavenger and antihepatotoxic activity of *Rosmarinus tomentosus*. *Planta Medica.* 1993; 59: 312-14.
- Paraschos S, Magiatis P, Mitakou S, Petraki K, Kalliaropoulos A, Maragkoudakis P, Mentis A, Sgouras D, Skaltsounis AL. *In vitro* and *in vivo* activities of Chios mastic gum extracts and constituents against *Helicobacter pylori*. *Antimicrob Agents Chemother.* 2007; 51: 551-59.
- Rao BK, Rao CH. Hypoglycemic and antihyperglycemic activity of *Syzygium alternifolium* (Wt.) Walp. seed extracts in normal and diabetic rats. *Phytomedicine* 2001; 8: 88-93.
- Sakurai K, Katoh M, Someno K, Fujimoto Y. Apoptosis and mitochondrial damage in INS-1 cells treated with alloxan. *Biol Pharm Bull.* 2001; 24: 876-82.
- Sushruta K, Satyanarayana S, Srinivas S, Sekhar JR. Evaluation of the blood-glucose reducing effects of aqueous extracts of the selected umbelliferous fruits used in culinary practices. *Tropical J Pharm Res.* 2007; 5: 613-17.
- Takahashi K, Fukazawa M, Motohira H, Ochiai K, Nishikawa H, Miyata T. A pilot study on antiplaque effects of mastic chewing gum in the oral cavity. *J Periodontol.* 2003; 74: 501-05.
- Triantafyllou A, Chaviaras N, Sergentanis TN, Protopapa E, Tsaknis J. Chios mastic gum modulates serum biochemical parameters in a human population. *J Ethnopharmacol.* 2007; 111: 43-49.

---

### Author Info

Usman Akhtar (Principal contact)  
e-mail: usmanakhtarpk@gmail.com; Tel: 00923224666868