



**BJP**

**Bangladesh Journal of Pharmacology**

**Research Article**

**Effects of *Alchemilla mollis* and  
*Alchemilla persica* on the wound  
healing process**

## Effects of *Alchemilla mollis* and *Alchemilla persica* on the wound healing process

Burçin Ergene Öz<sup>1</sup>, Mert İlhan<sup>2</sup>, Serkan Özbilgin<sup>1</sup>, Esra Küpeli Akkol<sup>2</sup>, Özlem Bahadır Acıkara<sup>1</sup>, Gülçin Saltan<sup>1</sup>, Hikmet Keleş<sup>3</sup> and Ipek Süntar<sup>2</sup>

<sup>1</sup>Department of Pharmacognosy, Faculty of Pharmacy, Ankara University, 06100, Ankara, Turkey; <sup>2</sup>Department of Pharmacognosy, Faculty of Pharmacy, Gazi University, Etiler 06330, Ankara, Turkey; <sup>3</sup>Department of Pathology, Faculty of Veterinary Medicine, Afyon Kocatepe University, 03200, Afyonkarahisar, Turkey.

### Article Info

Received: 21 December 2015  
Accepted: 9 May 2016  
Available Online: 3 June 2016  
DOI: 10.3329/bjp.v11i3.26024

### Cite this article:

Öz BE, İlhan M, Özbilgin S, Akkol EK, Acıkara OB, Saltan G, Keleş H and Süntar I. Effects of *Alchemilla mollis* and *Alchemilla persica* on the wound healing process. Bangladesh J Pharmacol. 2016; 11: 577-84.

### Abstract

*Alchemilla mollis*, is used in traditional medicine for the treatment of wounds and excessive menstruation. Aqueous methanol extracts of *A. mollis* and *A. persica* were evaluated for wound healing activity by using linear incision and circular excision wound models along with hydroxyproline estimation and histopathological analysis. Anti-inflammatory effect was determined according to Whittle method. The extracts prepared from the aerial parts of *A. mollis* and *A. persica* exerted significant wound healing activity with the tensile strength values of 39.3% and 33.3%, respectively, and with the contraction values of 51.4% and 43.5%, respectively. Hydroxyproline estimation and histopathological analysis also confirmed the results. The extracts of *A. mollis* and *A. persica* showed significant anti-inflammatory activity with the values of 30.6% and 26.6% respectively. These results showed that *A. mollis* and *A. persica* possess significant wound healing and anti-inflammatory activities.

## Introduction

*Alchemilla* genus plants are herbaceous perennial plants from the family *Rosaceae*, known as their common name "Lady's mantle". The most popular species of this genus is *A. vulgaris* L. The medicinal part of the plant is the aerial part, collected in flowering season, which is also recorded in ESCOP Monographs and approved by Commission E in order to be used against diarrhea as well as gastrointestinal complaints hemorrhoids and dysmenorrhoea and externally in the cases of stomatitis and wound healing (ESCOP Monographs, 2003; Gruenwald et al., 2000; Neagu et al., 2015). Indeed, in traditional medicine, *Alchemilla* species have been used internally for the treatment of menopausal complaints, dysmenorrhoea, gastrointestinal disorders, mouth and throat inflammation and externally for ulcers, eczema and skin rashes (Kupeli Akkol et al., 2015). One of these species, *A. mollis*, is used in traditional medicine for the

treatment of wounds and excessive menstruation (Makau et al., 2013; Trendafilova et al., 2011; Yarnel and Abascal, 2009). Previous studies on *A. mollis* have revealed that the plant has antiviral, astringent, diuretic, antispasmodic and anti-oxidant activities (Makau et al., 2013; Trendafilova et al., 2011) due to its phenolic content; tannins, flavonoid glycosides (Trendafilova et al., 2011).

This study was designed to screen the wound healing activity potential of two *Alchemilla* species namely, *A. mollis* and *A. persica*, growing wild in Turkey, by conducting *in vivo* bioassays.

## Materials and Methods

### Plant material

Both the aerial parts and roots of *A. mollis* and *A. persica*



were collected from Sivas Saryar village and Erzincan Kop passage, respectively and identified by Mehmet Tekin from Faculty of Science, Cumhuriyet University and Prof. Hayri Duman from Department of Biological Sciences, Faculty of Art and Sciences, Gazi University. Voucher specimen of *A. mollis* was deposited in Herbarium of Cumhuriyet University, Faculty of Science (CUFH 1344) and the voucher specimen of *A. persica* was kept in the Herbarium of Ankara University, Faculty of Pharmacy (AEF 25896).

#### Preparation of the extracts

Aerial parts and roots of the plants were separated, shade dried and powdered. Aqueous methanolic extracts were prepared with methanol: water (80:20) mixture by continuous stirring at 24°C for 8 hours. After filtration, extracts were concentrated to dryness under reduced pressure and low temperature (40-50°C) on a rotary evaporator to obtain crude extract. Yield percentages were as follows; 26.1%, 26.0% for *A. mollis* aerial parts and roots and 19.9%, 14.5% for *A. persica* aerial parts and roots, respectively.

#### Animals

Male Swiss albino mice (20–25 g) and Sprague-Dawley rats (160–180 g) provided from Laboratory Experimental Animals, Kobay, Turkey were left for 3 days for acclimatization into laboratory conditions and maintained on standard pellet diet and water *ad libitum*. For the evaluation of anti-inflammatory activity, the food was withdrawn on the day before the experiment, but free access to water was allowed. Six animals were used in each group. All experimental process was achieved at the Laboratory Animals Breeding and Experimental Researches Center, Faculty of Pharmacy, Gazi University.

#### Preparation of test samples

In the anti-inflammatory activity, test samples were given orally to the animals after suspending in a mixture of distilled water and 0.5% sodium carboxymethyl cellulose (CMC). Control group animals received the same experimental handling as those of the test groups except that the drug treatment was replaced with appropriate volumes of the dosing vehicle. Indomethacin (10 mg/kg) in 0.5% CMC was used as reference drug (Süntar et al., 2010).

For the evaluation of wound-healing activity, the test ointments were prepared by mixing the extracts with a mixture of ointment base consisting of glycol stearate: Propylene glycol and liquid paraffin (3:6:1) in a mortar thoroughly. Treatments were started immediately after the creation of wound by daily application of the test ointments on the wounded area. The control group animals were topically treated with ointment base, while the animals in negative control group were not treated with any product. Madecassol® (Bayer) (0.5 g)

was used topically as reference drug (Süntar et al., 2010).

#### Wound-healing activity

##### Linear incision wound model

Animals were anesthetized with 0.05 mL xylazine (2% Alfazine®) and 0.15 mL ketamine (10% Ketazol®) and the back hair of the rats were shaved and cleaned with 70% alcohol. Two 5 cm-length linear-paravertebral incisions were created with a sterile blade at the distance of 1.5 cm from the dorsal midline on each side. Three surgical sutures were placed each 1 cm apart.

The test ointments, the reference drug (Madecassol®) and ointment base were topically applied on the dorsal wounds in each group of animals once daily throughout 9 days. All the sutures were removed on the last day. Tensile strength of the treated skin was measured by using a tensiometer (Zwick/Roell Z0.5, Germany) (Lodhi et al., 2006; Süntar et al., 2010; Suguna et al., 2002).

##### Circular excision wound model

Mice were anesthetized with 0.02 mL xylazine (2% Alfazine®) and 0.08 mL ketamine (10% Ketazol®). The back was depilated by shaving. The circular wound was created on the dorsal interscapular region of each animal by excising the skin with a 5 mm biopsy punch (Nopa instruments, Germany); wounds were left open. Test samples, reference drug (Madecassol®, Bayer) and the vehicle ointments were applied topically once a day till the wounds completely healed. The progressive changes in wound areas were monitored by a camera (Fuji, S20 Pro, Japan) on alternate days. Wound areas were evaluated by using AutoCAD program. Wound contraction was calculated as percentage of the reduction in wounded area. A specimen sample of tissue was isolated from the healed skin of each group of mice for the histopathological analysis (Süntar et al., 2011).

#### Histopathology

The tissue specimens were fixed in 10% buffered formalin, processed and blocked with paraffin and then sectioned into 5 µm sections and stained with hematoxylin and eosin (HE) and Van Gieson (VG) stains. The tissues were examined by light microscope (Nicon Eclipse Ciattached Kameram® Digital image analyze system) and graded as mild (+), moderate (++) and severe (+++) for epidermal or dermal re-modeling. For this purpose, re-epithelization or ulcer in epidermis; fibroblast proliferation, mononuclear and/or polymorphonuclear cells, neovascularization and collagen depositions in dermis were analyzed. After examination, results were combined and staged for wound healing phases as inflammation, proliferation, and re-modeling in all groups.

### Hydroxyproline estimation

Tissues were dried in hot air oven at 60-70°C until consistent weight was achieved. Afterwards, samples were hydrolyzed with 6N HCl for 3 hours at 130°C. The hydrolyzed samples were adjusted to pH 7 and subjected to chloramin T oxidation. The colored adduct formed with Ehrlich reagent at 60°C was read at 557 nm. Standard hydroxyproline was also run and values reported as µg/mg dry weight of tissue (Süntar et al., 2012).

### Anti-inflammatory activity

Acetic acid-induced increase in capillary permeability (Whittle method)

Effect of the test samples on the increased vascular permeability induced by acetic acid in mice was determined according to the method (Whittle, 1964) with some modifications (Yesilada and Kupeli, 2007). Test samples were administered orally to a group of 10 mice in 0.2 mL/20 g body weight. Thirty min after the administration, tail of each animal was injected with 0.1 mL of 4% Evans blue in saline solution (i.v.) and waited for 10 min. Then, 0.4 mL of 0.5% (v/v) acetic acid solution was injected i.p. After 20 min incubation, the mice were killed by dislocation of the neck, and the viscera were exposed and irrigated with distilled water, which was then poured into 10 mL volumetric flasks through glass wool. Each flask was made up to 10 mL with distilled water, 0.1 mL of 0.1N NaOH solution was added to the flask, and the absorption of the final solution was measured at 590 nm (Beckmann Dual Spectrometer; Beckman, USA). A mixture of distilled water and 0.5% CMC was given orally to control animals, and they were treated in the same manner as described above.

### Determination of anti-oxidant activity and total phenolics

The anti-oxidant effect was assessed by using the 2,2-diphenyl-1-picrylhydrazyl (DPPH) radical scavenging assay. The samples and reference were dissolved in MeOH and mixed with DPPH solution (80 µg/mL). The amount of remaining DPPH was determined at 517 nm by using Spectrophotometer. Quercetin was used as reference compound. DPPH inhibitory activity was calculated according to the following formula:

$$\text{Inhibition (\%)} = (A_{\text{control}} - A_{\text{sample}}) \times 100 / A_{\text{control}}$$

where  $A_{\text{control}}$  was the absorbance of the control reaction (containing all reagents except the test sample), and  $A_{\text{sample}}$  was the absorbance of the test/reference

Experiments were run in duplicate and the results were expressed as inhibition values (Kumarasamy et al., 2003).

Total phenolic contents of the extracts were performed employing the methods involving Folin-Ciocalteu reagent and gallic acid as a standard (Spanos and Wrolstad, 1990). An amount of 100 µL test solution containing 1 mg of extract was transferred in a volumetric flask, distilled water and Folin-Ciocalteu reagent were added and flask was shaken thoroughly.  $\text{Na}_2\text{CO}_3$  solution (4 mL) was added and the mixture was allowed to stand for 2 hours with intermittent shaking at room temperature. Then the absorbance of the test solution was measured at 765 nm. The same procedure was repeated for various concentrations of gallic acid solutions (0.05 mg/mL; 0.1 mg/mL; 0.15 mg/mL; 0.25 mg/mL and 0.5 mg/mL) and standard curve was obtained.

### Statistical analysis

Data obtained from animal experiments were expressed as the mean standard error ( $\pm$  SEM). Statistical differences between the treated and the control groups were evaluated by ANOVA and Students-Newman-Keuls *post-hoc* tests.  $p < 0.05$  was considered to be significant. Histopathological data were considered to be nonparametric; therefore, no statistical tests were performed.

## Results

The extracts prepared from the aerial parts of *A. mollis* and *A. persica* exerted significant wound healing activity with the tensile strength values of 39.3% and 33.3%, respectively on the incision wound model, and with the contraction values of 51.4% and 43.5%, respectively on the excision wound model (Table I, II). According to histopathological analysis, reference group showed the best re-modelling comparing to the other groups. Lesser re-modelling were seen in the *A. mollis* aerial part extract, *A. persica* aerial part extract and *A. mollis* root extract groups, respectively. Limited healing processes were detected in the *A. persica* root extract, vehicle, and negative control groups (Table III). Histopathological results were presented in Figure 1. According to the results of hydroxyproline analysis, the aerial part extracts of *A. mollis* and *A. persica* were found to possess higher hydroxyproline content than the other groups (Table IV).

In the anti-inflammatory activity assessment, the aerial part extracts of *A. mollis* and *A. persica* showed significant anti-inflammatory activity with the values of 30.6% and 26.6% respectively, at 200 mg/kg dose (Table V). On the other hand, the aerial part extract of *A. mollis* demonstrated the best DPPH radical scavenging activity ( $\text{IC}_{50} = 39.5$  µg/mL) with the highest phenolic content (72.4 mg GAL/g) (Table VI).

Table I

Effects of the extracts of *A. mollis* and *A. persica* on linear incision wound model

Material	Parts used	Statistical data (mean ± SEM)	%Tensile strength
Vehicle	-	10.3 ± 2.1	3.6
Negative control	-	9.9 ± 2.3	-
<i>A. mollis</i>	Aerial parts	14.3 ± 1.8	39.3 <sup>b</sup>
<i>A. mollis</i>	Roots	12.6 ± 2.0	22.6 <sup>a</sup>
<i>A. persica</i>	Aerial parts	13.7 ± 2.0	33.3 <sup>b</sup>
<i>A. persica</i>	Roots	11.5 ± 2.2	11.4
Madecassol®	-	16.0 ± 1.2	55.1 <sup>c</sup>

<sup>a</sup>p<0.05; <sup>b</sup>p<0.01; <sup>c</sup>p<0.001; Percentage of tensile strength values: Vehicle group was compared to negative control group; Extracts were compared to vehicle group

Table II

Effects of the extracts of *A. mollis* and *A. persica* on circular excision wound model

Wound area ± SEM (%Contraction)								
Material	Parts used	Day 0	Day 2	Day 4	Day 6	Day 8	Day 10	Day 12
Vehicle	-	20.0 ± 2.1	18.1 ± 1.7	17.4 ± 2.0	16.0 ± 2.0	11.9 ± 1.4	7.7 ± 1.3	3.9 ± 0.7
			-	(5.6)	-	(4.2)	(1.7)	(1.8)
Negative control	-	19.8 ± 2.3	18.0 ± 1.8	17.9 ± 2.0	15.6 ± 1.8	12.4 ± 1.7	7.8 ± 1.5	4.0 ± 1.0
<i>A. mollis</i>	Aerial parts	19.7 ± 2.2	17.2 ± 1.2	16.2 ± 1.9	13.3 ± 2.0	8.7 ± 1.5	4.6 ± 1.0	1.9 ± 0.3
			(5.0)	(6.9)	(16.9)	(26.3)	(39.6) <sup>a</sup>	(51.4) <sup>b</sup>
<i>A. mollis</i>	Roots	19.8 ± 2.0	17.5 ± 1.4	16.6 ± 2.0	13.9 ± 2.0	9.9 ± 1.6	5.9 ± 1.3	2.7 ± 0.5
			(3.6)	(5.0)	(12.9)	(16.4)	(23.7)	(30.4) <sup>a</sup>
<i>A. persica</i>	Aerial parts	19.9 ± 2.1	18.2 ± 1.8	17.0 ± 1.7	14.0 ± 1.6	9.3 ± 1.5	5.1 ± 1.0	2.2 ± 0.3
			-	(2.4)	(12.1)	(21.6)	(33.0) <sup>a</sup>	(43.5) <sup>b</sup>
<i>A. persica</i>	Roots	20.1 ± 2.3	18.2 ± 1.7	17.6 ± 2.0	14.9 ± 1.8	10.9 ± 1.9	6.3 ± 1.4	3.1 ± 0.9
			-	-	(7.0)	(8.0)	(17.8)	(18.7)
Madecassol®	-	19.8 ± 2.2	15.3 ± 1.3	13.5 ± 1.5	9.9 ± 1.1	4.2 ± 0.7	1.9 ± 0.7	0.0 ± 0.0
			(15.5)	(22.7)	(37.8) <sup>a</sup>	(64.4) <sup>b</sup>	(75.4) <sup>c</sup>	(100.0) <sup>c</sup>

<sup>a</sup>p<0.05; <sup>b</sup>p<0.01; <sup>c</sup>p<0.001; Percentage of contraction values: Vehicle group was compared to negative control group; Extracts were compared to vehicle group

## Discussion

In the present study, wound healing activity of *A. mollis* and *A. persica*, both of which have quite similar phytochemical profile according to our previous research (Kupeli Akkol et al., 2015), were selected in order to be evaluated by using *in vivo* wound models. The extracts prepared from the aerial parts of *A. mollis* and *A. persica* displayed significant wound healing effect with regard to the contraction and tensile strength values, as well as histopathological and hydroxyproline analysis. The aerial part extracts of *A. mollis* and *A. persica* demonstrated remarkable anti-inflammatory activity; the aerial part extract of *A. mollis*

showed significant anti-oxidant effect.

In the previous studies on *A. mollis*, hyperoside, isoquercetin, cis- and trans-tiliroside, sinocrossoside D2 and rhodiogin were isolated from the ethyl acetate extract of the flowering aerial parts (Trendafilova et al., 2012; Trendafilova et al., 2011). By using liquid chromatography-tandem mass spectrometry technique, monomeric and oligomeric ellagitannins were identified in acetone/water extracts obtained from the leaves of *A. mollis* (Duckstein et al., 2012). In our previous study, hyperoside and isoquercetin quantification in aqueous methanolic extracts of *A. mollis* and *A. persica* was conducted by HPLC. Some phenolics such as

**Table III**  
**Wound healing processes and healing phases of the experimental groups**

Groups	Parts used	Wound Healing Processes										Healing Phases				
		S	U	RE	FP	CD	MNC	PMN	NV	I	P	R				
Vehicle	-	+++	++/+++	-	+++	++/+++	++/+++	++/+++	++/+++	++/+++	++/+++	++/+++	++/+++	++/+++	++/+++	-
Negative control	-	+++	+++	-	+++	++/+++	++/+++	++/+++	++/+++	++/+++	++/+++	++/+++	++/+++	++/+++	++/+++	-
<i>A. mollis</i>	AE	++	-	+	++/+++	++	++/+++	++/+++	++/+++	++/+++	++/+++	++/+++	++/+++	++/+++	++/+++	+
<i>A. mollis</i>	R	++/+++	-/+	-/+	++/+++	++/+++	++/+++	++/+++	++/+++	++/+++	++/+++	++/+++	++/+++	++/+++	++/+++	-/+
<i>A. persica</i>	AE	++/+++	-/+	-/+	++/+++	++	++/+++	++/+++	++/+++	++/+++	++/+++	++/+++	++/+++	++/+++	++/+++	-/+
<i>A. persica</i>	R	++/+++	+ / ++	-	++/+++	+++	++/+++	++/+++	++/+++	++/+++	++/+++	++/+++	++/+++	++/+++	++/+++	-
Madecassol®	-	++	-	+	++	++	++	+	+/+++	+/+++	+/+++	+/+++	+/+++	+/+++	++	+

HE and VG stained sections were scored as mild (+), moderate (++) and severe (+++) for epidermal and/or dermal re-modeling. S: Scab, U: Ulcus, RE: Re-epithelization, FP: Fibroblast proliferation, CD: Collagen depositions, MNC: Mononuclear cells, PMN: Polymorphonuclear cells, NV: Neovascularization, I: Inflammation phase, P: Proliferation phase, R: Re-modelling phase.  
 AE: Aerial Parts; R: Roots

Table IV		
Effects of the test ointments of <i>A. mollis</i> and <i>A. persica</i> on hydroxyproline content		
Material	Parts used	Hydroxyproline (µg/mg)
Vehicle	-	13.4 ± 2.0
Negative control	-	11.8 ± 2.5
<i>A. mollis</i>	Aerial parts	28.1 ± 0.9 <sup>a</sup>
<i>A. mollis</i>	Roots	16.3 ± 2.2
<i>A. persica</i>	Aerial parts	25.9 ± 1.0 <sup>a</sup>
<i>A. persica</i>	Roots	15.1 ± 2.5
Madecassol®	-	44.3 ± 0.8 <sup>c</sup>

Data are mean ± SEM; <sup>a</sup>p<0.05; <sup>b</sup>p<0.01; <sup>c</sup>p<0.001; Vehicle group was compared to negative control group; Extracts were compared to vehicle group

caffeic acid, ferulic acid, orientin, rutin, hyperoside, isoquercitrin, luteolin-7-glycoside, myricetin and apigenin were investigated in *A. mollis* and *A. persica* by a developed and validated HPLC method. Hyperoside and isoquercitrin which are the major components of the aerial parts of the both species were quantified as 0.2 ± 0.002 mg and 0.6 ± 0.003 mg, respectively *A. Mollis*; and 0.2 ± 0.001 mg and 0.5 ± 0.001 mg respectively in *A. persica* for 100 mg plant material. In consequence, the phytochemical profiles of *A. mollis* and *A. persica* were found to be similar in terms of their HPLC chromatograms (Kupeli Akkol et al., 2015).

Previously, Shrivastava and John (2006) studied the wound healing activity of Aphtarine® which contains standard 3% extract of *A. vulgaris* for the treatment of aphthous ulcers clinically. Topical application of Aphtarine® gel to minor mouth ulcers relieved discomfort and produced complete healing in the majority of patients within 2 days (Shrivastava and

Table VI		
DPPH scavenging activity and total phenolic content of the extracts of <i>A. mollis</i> and <i>A. persica</i>		
Material	IC <sub>50</sub> (µg/mL)	Phenolic content (mg GAL/g)
<i>A. mollis</i> (Aerial parts)	39.4	72.4 ± 3.8
<i>A. Mollis</i> (Roots)	114.6	21.4 ± 2.9
<i>A. persica</i> (Aerial parts)	82.7	56.4 ± 2.5
<i>A. persica</i> (Roots)	156.3	20.6 ± 3.2
Reference (Quercetin)	3.1	-

John, 2006). In another study by the same authors, hydroglycerinated extract of *A. vulgaris* was shown to enhance myofibroblast and epithelial cell growth in both *in vivo* and *in vitro* models (Shrivastava et al., 2007). According to the phytochemical analysis quercetin glycosides were isolated from *A. vulgaris* (D'Agostino et al., 1998), which reveals a similar phytochemical profile with the two *Alchemilla* species, *A. mollis* and *A. persica*, used as the plant materials of the present research. Therefore, it could be concluded that flavonoid type compounds could also be responsible from the activity of these both species. Indeed, in a previous study, wound healing activity potential of the ethyl acetate fraction obtained from the ethanolic extract of the aerial parts of *Hypericum perforatum* was attributed to hyperoside, isoquercitrin, rutin and (-)-epicatechin besides the naphthodianthron type compounds (Süntar et al., 2010). The results of the present study was found to be in accord with those previous findings.

According to the literature survey, *Alchemilla* species were screened for other biological activities. For instance, inhibitory effect of *A. mollis* against influenza

Table V				
Inhibitory effect of the extracts of <i>A. mollis</i> and <i>A. persica</i> on acetic acid-induced increase in capillary permeability				
Material	Parts used	Dose (mg/kg)	Evans blue concentration (mg/mL)	Inhibition (%)
Control	-		13.2 ± 1.3	
<i>A. mollis</i>	Aerial parts	100	10.7 ± 0.9	19.2
<i>A. mollis</i>	Aerial parts	200	9.2 ± 0.7	30.6 <sup>b</sup>
<i>A. mollis</i>	Roots	100	12.5 ± 1.1	5.3
<i>A. mollis</i>	Roots	200	12.3 ± 1.0	7.4
<i>A. persica</i>	Aerial parts	100	11.7 ± 1.3	11.5
<i>A. persica</i>	Aerial parts	200	9.7 ± 0.9	26.6 <sup>a</sup>
<i>A. persica</i>	Roots	100	14.5 ± 1.1	-
<i>A. persica</i>	Roots	200	12.8 ± 0.9	3.6
Indomethacin		10	5.6 ± 0.5	58.0 <sup>c</sup>

Data are mean ± SEM; <sup>a</sup>p<0.05; <sup>b</sup>p<0.01; <sup>c</sup>p<0.001; significant from the control

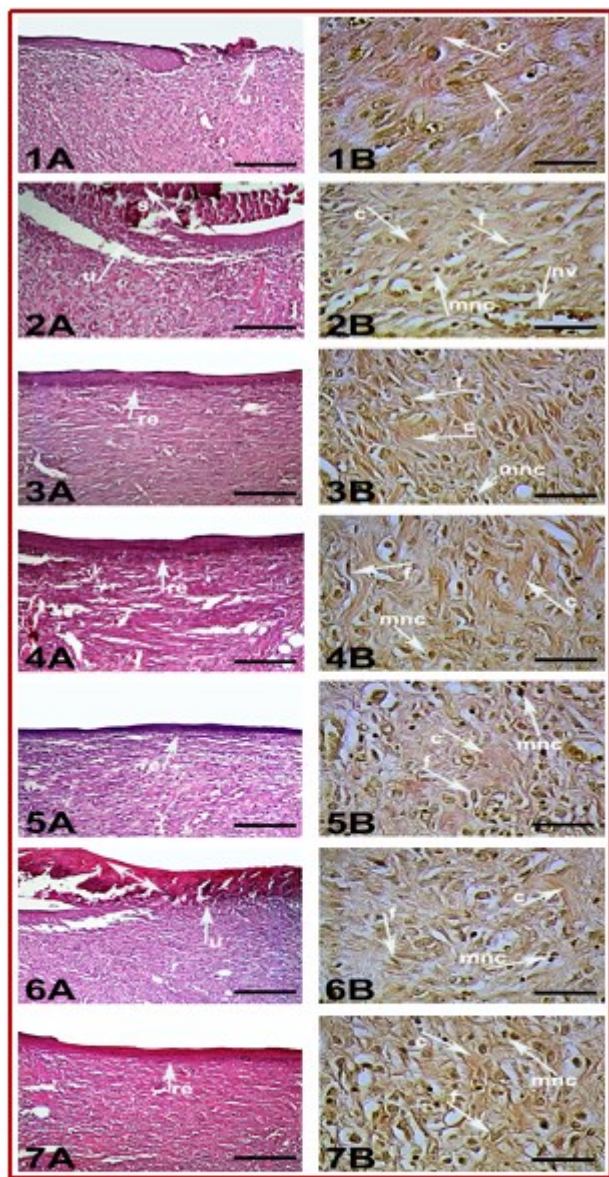


Figure 1: Histopathological view of wound healing and epidermal/dermal re-modeling in the test material administered animals.

Skin sections show the hematoxylin & eosin (HE) stained epidermis and dermis in A, and the dermis stained with Van Gieson (VG) in B. The original magnification was x100 and the scale bars represent 120  $\mu$ m for figures in A, and the original magnification was x400 and the scale bars represent 40  $\mu$ m for B. Data are representative of 6 animal per group. 1) Vehicle group, 2) Negative Control group, 3) *A. mollis* AE, 4) *A. mollis* R; 5) *A. persica* AE, 6) *A. persica* R, 7) Madecassol®. Arrows pointing events during wound healing; s: Scab, u: Ulcus, re: Re-epithelization, f: Fibroblast, c: Collagen, mnc: Mononuclear cells, nv: Neovascularization

A virus subtypes H1N1, H3N2, and H5N2 was shown in the study reported by Makau et al. (2013). The results demonstrated that *A. mollis* extract exhibited virucidal activity against influenza virus particles (Makau et al., 2013). Moreover, anti-oxidant activities of *A. mollis* and *A. persica* were investigated by Trendafilova et al. (2011) and Ergene et al. (2010), respectively. It was reported

that potent free radical scavenging activity of *A. mollis* extract was due to its phenolic content; tannins, flavonoid glycosides (Trendafilova et al., 2011). Additionally, it was demonstrated that aqueous methanolic extract prepared from the aerial part of *A. persica* possessed significant anti-oxidant activity by scavenging DPPH radical and reducing MDA level (Ergene et al., 2010). The data obtained from the present study was in accord with those previous findings. Recent researches have also pointed out that, isoquercitrin and hyperoside possess potent anti-oxidant activity (Kim et al., 2011; Valentova et al., 2014). Due to the strong relationship between wound healing and anti-oxidant activity (Getie et al., 2002; Shetty et al., 2008), wound healing potential of *A. mollis* and *A. persica* could be attributed to their flavonoid glycosides especially, hyperoside and isoquercitrin.

## Conclusion

*A. mollis* and *A. persica* possess significant wound healing and anti-inflammatory activities.

## Financial Support

Self-funded

## Ethical Issue

The study was performed according to the international rules considering the animal experiments and biodiversity rights (G.U.ET-08.037).

## Conflict of Interest

Authors declare no conflict of interest

## References

- Akbulut S, Bayramoglu MM. The trade and use of some medical and aromatic herbs in Turkey. *Stud Ethno-Med.* 2013; 7: 67-77.
- Baytop T. Therapy with medicinal plants in Turkey: Today and in future. Istanbul, Nobel Publishers, 1999.
- D'Agostino M, Dini I, Ramundo E, Senatore F. Flavonoid glycosides of *Alchemilla vulgaris* L. *Phytother Res.* 1998; 12: 162-63.
- Duckstein SM, Lotter EM, Meyer U, Lindequist U, Stintzing FC. Phenolic constituents from *Alchemilla vulgaris* L. and *Alchemilla mollis* (Buser) Rothm. at different dates of harvest. *Z. Naturforsch C.* 2012; 67: 529-40.
- Ergene B, Bahadır Acikara Ö, Bakar F, Saltan G, Nebioğlu S. Anti-oxidant activity and phytochemical analysis of *Alchemilla persica* Rothm. *J Fac Pharm Ankara.* 2010; 39: 145-



- 54.
- ESCOP Monographs: The scientific foundation for herbal medicinal products. United Kingdom, 2003.
- Getie M, Gebre-Mariam T, Rietz R, Neubert RH. Evaluation of the release profiles of flavonoids from topical formulations of the crude extract of the leaves of *Dodonaea viscosa* (Sapindaceae). *Pharmazie* 2002; 57: 320-22.
- Gruenwald J, Brendler T, Jaenicke C. Physician's desk reference for herbal medicines (PDR). USA, Medical Economics Company, 2000.
- Kim SJ, Um JY, Lee JY. Anti-inflammatory activity of hyperoside through the suppression of nuclear factor- $\kappa$ B activation in mouse peritoneal macrophages. *Am J Chin Med.* 2011; 39: 171-81.
- Kumarasamy Y, Nahar L, Cox PJ, Jaspars M, Sarker SD. Bio-activity of secoiridoid glycosides from *Centaurium erythraea*. *Phytomedicine* 2003; 10: 344-47.
- Kupeli Akkol E, Demirel MA, Bahadir Acikara O, Süntar I, Ergene B, İlhan M, Özbilgin S, Saltan G, Keles H, Tekin M. Phytochemical analyses and effects of *Alchemilla mollis* (Buser) Rothm. and *Alchemilla persica* Rothm. in rat endometriosis model. *Arch Gynecol Obstet.* 2015; 292: 619-28.
- Lodhi S, Pawar RS, Jain AP, Singhai AK. Wound healing potential of *Tephrosia purpurea* (Linn.) Pers. in rats. *J Ethnopharmacol.* 2006; 108: 204-10.
- Makau JN, Watanabe K, Kobayashi N. Anti-influenza activity of *Alchemilla mollis* extract: Possible virucidal activity against influenza virus particles. *Drug Discov Ther.* 2013; 7: 189-95.
- Neagu E, Paun G, Albu C, Radu GL. Assessment of acetylcholinesterase and tyrosinase inhibitory and anti-oxidant activity of *Alchemilla vulgaris* and *Filipendula ulmaria* extracts. *J Taiwan Inst Chem E.* 2015; 52: 1-6.
- Shetty S, Udupa S, Udupa L. Evaluation of anti-oxidant and wound healing effects of alcoholic and aqueous extract of *Ocimum sanctum* Linn in rats. *Evid Based Complement Alternat Med.* 2008; 5: 95-101.
- Shrivastava R, Cucuat N, John GW. Effects of *Alchemilla vulgaris* and glycerine on epithelial and myofibroblast cell growth and cutaneous lesion healing in rats. *Phytother Res.* 2007; 21: 369-73.
- Shrivastava R, John GW. Treatment of aphthous stomatitis with topical *Alchemilla vulgaris* in glycerine. *Clin Drug Investig.* 2006; 26: 567-73.
- Spanos GA, Wrolstad RE. Influence of processing and storage on the phenolic composition of thompson seedless grape juice. *J Agric Food Chem.* 1990; 38: 1565-71.
- Suguna L, Singh S, Sivakumar P, Sampath P, Chandrakasan G. Influence of *Terminalia chebula* on dermal wound healing in rats. *Phytother Res.* 2002; 16: 227-31.
- Süntar I, Akkol EK, Keles H, Oktem A, Baser KHC, Yesilada E. A novel wound healing ointment: A formulation of *Hypericum perforatum* oil and sage and oregano essential oils based on traditional Turkish knowledge. *J Ethnopharmacol.* 2011; 134: 89-96.
- Süntar IP, Kupeli Akkol E, Yilmazer D, Baykal T, Kirmizibekmez H, Alper M, Yesilada E. Investigations on the *in vivo* wound healing potential of *Hypericum perforatum* L. *J Ethnopharmacol.* 2010; 127: 468-77.
- Süntar I, Kupeli Akkol E, Keles H, Yesilada E, Sarker SD, Arroo R, Baykal T. Efficacy of *Daphne oleoides* subsp. *kurdistana* used for wound healing: Identification of active compounds through bioassay guided isolation technique. *J Ethnopharmacol.* 2012; 141: 1058-70.
- Trendafilova A, Todorova M, Gavrilova A, Vitkova A. Flavonoid glycosides from Bulgarian endemic *Alchemilla achtarowii* Pawl. *Biochem Syst Ecol.* 2012; 43: 156-58.
- Trendafilova A, Todorova M, Nikolova M, Gavrilova A, Vitkova A. Flavonoid constituents and free radical scavenging activity of *Alchemilla mollis*. *Nat Prod Commun.* 2011; 6: 1851-54.
- Valentova K, Vrba J, Bancirova M, Ulrichova J, Kren V. Isoquercitrin: Pharmacology, toxicology, and metabolism. *Food Chem Toxicol.* 2014; 68: 267-82.
- Whittle BA. The use of changes in capillary permeability in mice to distinguish between narcotic and non-narcotic analgesics. *Br J Pharmacol.* 1964; 22: 246-53.
- Yarnel E, Abascal K. Multiphasic herbal prescribing for menstruating women. *Alternat Complement Ther.* 2009; 15: 126-34.
- Yesilada E, Kupeli E. *Clematis vitalba* L. aerial part exhibits potent anti-inflammatory, anti-nociceptive and anti-pyretic effects. *J Ethnopharmacol.* 2007; 110: 504-15.

**Author Info**

Ipek Süntar (Principal contact)  
e-mail: ipesin@gazi.edu.tr